

Iiris Sorri

**Effects Of Antiepileptic Drugs on Visual Function, with Special
Reference to Vigabatrin**

A Clinical Study

Doctoral dissertation

To be presented by permission of the Faculty of Medicine of the University
of Kuopio for public examination in Auditorium L23, Snellmania Building
of the University of Kuopio,
on Saturday 24th November 2001, at 12 noon

Department of Ophthalmology, University of Kuopio
Department of Neurology, University of Kuopio
Department of Ophthalmology, Kuopio University Hospital
Department of Neurology, Kuopio University Hospital

Distributor: Kuopio University Library
P.O.Box 1627
Fin-70211 Kuopio
Finland
Tel. +358 17 163 430
Fax +358 17 163 410

Series editors: Professor Esko Alhava, M.D., Ph.D.
Department of Surgery

Professor Martti Hakumäki, M.D., Ph.D.
Department of Physiology

Author's address: Department of Ophthalmology
Kuopio University Hospital
P.O.Box 1777
FIN-70211 Kuopio, Finland
Tel. +358 17 172 800
Fax +358 17 172 486

Supervisors: Professor Maija Mäntyjärvi, M.D., Ph.D.
Department of Ophthalmology
University of Kuopio

Docent Reetta Kälviäinen, M.D., Ph.D.
Department of Neurology
University of Kuopio and Kuopio University Hospital

Reviewers: Docent Eila Mustonen, M.D., Ph.D.
Department of Ophthalmology
University of Oulu

Docent Tapani Keränen, M.D., Ph.D.
Department of Neurology
University of Turku

Opponent: Docent Hannu Uusitalo, M.D., Ph.D.
Department of Ophthalmology
University of Tampere

ISBN 951-781-859-9
ISSN 1235-0303

Kuopio University Printing Office
Kuopio 2001
Finland

Sorri, Iiris. Effects of Antiepileptic Drugs on Visual Function, with Special Reference to Vigabatrin: A Clinical Study. Kuopio University Publications D. Medical Sciences 259. 2001. 104 p.
ISBN 951-781-859-9
ISSN 1235-0303

ABSTRACT

Epilepsy is a common neurological disease characterized by recurrent, usually unprovoked seizures due to excessive discharge of cerebral neurons. Medical therapy is the standard treatment for the majority of epilepsy patients. New antiepileptic drugs (AED), vigabatrin (VGB) and tiagabine (TGB) among others, have entered the market in recent years as a result of rational drug development. VGB and TGB increase the amount of inhibitory neurotransmitter, gamma-amino butyric acid (GABA), in the central nervous system, with different specific mechanisms of action. VGB is a selective irreversible inhibitor of GABA-transaminase and TGB blocks the neuronal and glial reuptake of GABA. They are approved for the adjunctive management of partial epilepsy, and in addition VGB is approved for initial monotherapy in the management of infantile spasms, and for seizures caused by tuberous sclerosis. Since 1997, reports of severe concentric visual field defects in association with the use of VGB have been published. The purpose of the present study was to determine the causality, prevalence, risk factors and prognosis of visual field defects in patients treated with initial VGB monotherapy or with VGB add-on therapy. The effect of TGB monotherapy on visual fields was examined in order to detect any possible class effect of GABAergic AEDs. In addition, visual functions were assessed more comprehensively with psychophysical tests in patients with VGB, TGB or carbamazepine (CBZ) monotherapy.

Kinetic visual fields were examined in 35 epilepsy patients (aged 20-74 years) on VGB monotherapy, in 25 patients (aged 17-62 years) on VGB add-on therapy, in 15 patients (aged 31-71 years) on TGB monotherapy, in 18 patients (aged 20-70 years) on CBZ monotherapy, and in 18 healthy controls (aged 23-74 years). Color vision and contrast sensitivity tests were performed in 32 epilepsy patients on VGB monotherapy, and in the patients on TGB or CBZ monotherapy. The prognosis of VGB-associated visual field defects was evaluated in a follow-up examination after 4 to 38 months in 55 patients, 29 of whom had discontinued VGB therapy. Visual fields were graded as normal, mildly constricted or severely constricted according to their temporal extents.

Bilateral concentric visual field constriction was found in 24 of 60 (40%) patients treated with VGB therapy. The constriction was severe in 8 (13%) and mild in 16 (27%) patients. There was no difference between monotherapy and add-on therapy groups. Statistical analysis showed that concentric constriction of the visual fields was related to the use of VGB. The extents of the visual fields were significantly constricted in the VGB monotherapy group as compared with the visual fields of patients in the CBZ monotherapy group or healthy controls ($p < 0.01$). Most patients were asymptomatic. Visual field defects were neither reversible after cessation of the drug nor progressive with continued treatment. The patients on TGB monotherapy or on CBZ monotherapy had no concentric visual field defects. Acquired color vision defects were found in 32% of VGB monotherapy patients, in 50% of TGB monotherapy patients, and in 28% of CBZ monotherapy patients. Color vision and contrast sensitivity were significantly impaired in patients who had VGB-associated visual field defects. Contrast sensitivity was not affected by TGB or CBZ.

The findings of the present study confirm the relationship between AED treatment with VGB and concentric visual field defects, and the irreversible nature of these defects. Neither clear risk factors nor a class effect of GABAergic AEDs was found. All the AEDs studied may cause impairment in visual function, but the most significant changes were found in patients who received long-term VGB treatment, supporting the idea of the retinal toxicity of VGB. The exact mechanism of VGB-associated visual field defects is not clear and future research should elucidate the pathophysiological mechanism of the toxicity of VGB. If VGB is used, regular visual field examination should be performed before the start of treatment and at regular intervals during treatment.

National Library of Medicine Classification: WW 105, QV 85

Medical Subject Headings: anticonvulsants/adverse effects; carbamazepine; color perception/drug effects; contrast sensitivity/drug effects; epilepsies, partial/drug therapy; glare; perimetry; vigabatrin/adverse effects; visual fields/drug effects

To Leena and Jussi

ACKNOWLEDGEMENTS

This study was carried out at the Departments of Ophthalmology, Neurology, Neuroradiology and Clinical Neurophysiology in the University of Kuopio and Kuopio University Hospital and at the Department of Ophthalmology in Turku University Hospital during years 1997-2001.

I wish to express my deepest gratitude to the supervisor of this thesis, Professor Maija Mäntyjärvi, M.D., Ph.D., Head of the Department of Ophthalmology in the University of Kuopio, for providing me research facilities. She introduced me to the research methods concerning visual functions and gave valuable comments and support during this work.

My warmest thanks I express to my supervisor, Docent Reetta Kälviäinen, M.D., Ph.D. Despite her busy schedules she had always time to give me guidance and feedback throughout this work.

I am thankful to Professor Paavo Riekkinen Sr., M.D., Ph.D. for his support and encouragement during this study.

I owe my warm thanks to Docent Markku Teräsvirta, M.D., Ph.D., Head of the Department of Ophthalmology in Kuopio University Hospital, for the opportunity to do this work in the clinic and for his support during the study.

I am greatly indebted to Professor Eeva Nikoskelainen, M.D., Ph.D. for the neuro-ophthalmological examinations, to Docent Kaarina Partanen, M.D., Ph.D. for the neuroradiological examinations and to Professor Juhani Partanen M.D., Ph.D. for the electrophysiological examinations.

I wish to acknowledge sincerely Docent Eila Mustonen, M.D., Ph.D. and Professor Tapani Keränen, M.D., Ph.D., the official reviewers of this thesis, for their constructive criticism.

I express my sincere gratitude to Pirjo Halonen, M.Sc. for her expert advice and help in statistical analyses, to Mrs. Liisi Saarela for help in editing the manuscript and to Vivian Paganuzzi, M.A. for revising the language.

My special thanks go to Ms. Mari Hänninen R.N., Mrs. Terttu Myöhänen R.N., Mrs. Pilvi Pehkonen, R.N. and Mrs. Virpi Savolainen R.N. for their practical help during the study. I also wish thank the staff of the Departments of Ophthalmology and Neurology in Kuopio University Hospital for their help and positive attitude during this work.

I am grateful to the personnel of the Library of the University of Kuopio for their kind and professional service.

I express my gratitude to all the patients who have participated in this study.

I wish to express my deepest thanks to my dear mother Edla Hänninen, to my late father Kalervo Hänninen who did not see this thesis completed, and to my sisters and brothers and their families for their support and encouragement during this work. Special thanks go to my brother Anssi Hänninen, for his practical help with the computer.

My warmest thanks I owe to my beloved children Leena and Jussi for their patience and kind support during this study.

This study was financially supported by the Eye and Tissue Banking Foundation (Silmä- ja kudospankkisäätiö), the Finnish Eye Foundation (Silmäsäätiö), De Blindas Vänner r.f. - Sokeain Ystävät r.y., University of Kuopio and Kuopio University Hospital.

Kuopio, October 2001

Iiris Sorri

ABBREVIATIONS

ACD	Anticonvulsant drug
AED	Antiepileptic drug
ANOVA	Analysis of variance
AO-HRR	American Optical, Hardy-Rand-Rittler Pseudoisochromatic plates
AQ	Anomalous quotient
BAT	Brightness acuity test
CBZ	Carbamazepine
cd	Candela
CI	Confidence interval
CVM	Color Vision Meter
CNS	Central nervous system
cpd	Cycles per degree
CPMP	Committee for Proprietary Medicinal Products
CSF	Cerebrospinal fluid
CT	Computerized tomography
D	Diopter
dB	Decibel
DPH	Phenytoin
EOG	Electro-oculogram
ERG	Electroretinogram
FM100	Farnsworth-Munsell 100 Hue Test
GABA	Gamma-amino butyric acid
GABA-T	GABA-transaminase
GAD	Glutamic acid decarboxylase
GAT	GABA-transporter
GCL	Ganglion cell layer
ILAE	International League Against Epilepsy
INL	Inner nuclear layer
IPL	Inner plexiform layer
LE	Left eye
MMP	Mid matching point
MR	Matching range
MRI	Magnetic resonance imaging
ONL	Outer nuclear layer
OPL	Outer plexiform layer
SD	Standard deviation
SPP2	Standard Pseudoisochromatic Plates Part two
RE	Right eye
RPE	Retinal pigment epithelium
TES	Total error score
TGB	Tiagabine
VA	Visual acuity
VEP	Visual evoked potentials
VGB	Vigabatrin
VPA	Valproic acid

LIST OF ORIGINAL PUBLICATIONS

This thesis is based on the following original publications referred to in the text by their Roman numerals I-V.

- I** Kälviäinen R, Nousiainen I, Mäntyjärvi M, Nikoskelainen E, Partanen J, Partanen K, Riekkinen P Sr. Vigabatrin, a gabaergic antiepileptic drug, causes concentric visual field defects. *Neurology* 1999;53:922-926.
- II** Nousiainen I, Mäntyjärvi M, Kälviäinen R. No reversion in vigabatrin-associated visual field defects. *Neurology* 2001;57:1916. In press.
- III** Nousiainen I, Kälviäinen R, Mäntyjärvi M. Contrast and glare sensitivity in epilepsy patients treated with vigabatrin or carbamazepine monotherapy compared with healthy volunteers. *British Journal of Ophthalmology* 2000;84:622-625.
- IV** Nousiainen I, Kälviäinen R, Mäntyjärvi M. Color vision in epilepsy patients treated with vigabatrin or carbamazepine monotherapy. *Ophthalmology* 2000;107:884-888.
- V** Nousiainen I, Mäntyjärvi M, Kälviäinen R. Visual function in patients treated with the GABAergic anticonvulsant drug tiagabine. *Clinical Drug Investigation* 2000;20:393-400.

CONTENTS

1	INTRODUCTION	17
2	REVIEW OF THE LITERATURE	19
2.1	Anatomy and physiology of the retina	19
2.1.1	Overview	19
2.1.2	GABA and GABAergic cells in the retina	21
2.2	Visual function tests	22
2.2.1	Overview	22
2.2.2	Visual fields	23
2.2.3	Contrast sensitivity	25
2.2.4	Glare sensitivity	25
2.2.5	Color vision	26
2.3	Epilepsy and antiepileptic therapy with vigabatrin, tiagabine and carbamazepine	27
2.3.1	Epilepsy	27
2.3.2	Vigabatrin	28
2.3.3	Tiagabine	29
2.3.4	Carbamazepine	30
2.4	The influence of vigabatrin on the visual system	30
2.4.1	Retina and visual pathways	30
2.4.2	Visual fields	32
2.4.2.1	Characteristics of vigabatrin-associated visual field defects	33
2.4.2.2	Symptoms	35
2.4.2.3	Prevalence of vigabatrin-associated visual field defects	36
2.4.2.4	Risk factors for vigabatrin-associated visual field defects	37
2.4.2.5	Visual field defects in children treated with vigabatrin	38
2.4.2.6	Prognosis of vigabatrin-associated visual field defects	39
2.4.3	Contrast and glare sensitivity	40
2.4.4	Color vision	40
2.4.5	Dark adaptation	41
2.4.6	Ophthalmological findings	41

2.4.7	Electrophysiological changes	42
2.4.7.1	Visual evoked potentials	42
2.4.7.2	Electroretinogram	43
2.4.7.3	Electro-oculogram	44
2.5	The influence of tiagabine on the visual system	44
2.5.1	Retina	44
2.5.2	Visual fields	45
2.5.3	Visual function tests	46
2.6	The influence of carbamazepine on the visual system	46
2.6.1	Retina	46
2.6.2	Visual fields	47
2.6.3	Contrast and glare sensitivity	47
2.6.4	Color vision	47
2.6.5	Dark adaptation	48
2.6.6	Electrophysiological changes	48
3	AIMS OF THE STUDY	49
4	PATIENTS AND METHODS	50
4.1	Study design	50
4.2	Patients	50
4.3	Controls	52
4.4	Approval of the Ethics Committee	52
4.5	Ophthalmological examination (I-V)	53
4.6	Visual field examination	53
4.6.1	Kinetic perimetry (I-V)	53
4.6.2	Static perimetry (V)	55
4.7	Contrast sensitivity (III,V)	55
4.8	Glare sensitivity (III)	55
4.9	Color vision (IV-V)	56
4.9.1	Standard Pseudoisochromatic Plates 2	56
4.9.2	Farnsworth-Munsell 100 Hue test	56
4.9.3	Color Vision Meter 712 anomaloscope	57
4.10	Dark adaptation (III)	57
4.11	Electroretinogram (I)	57

4.12	Neuroradiology (I)	58
4.13	Statistical methods (I-V)	58
5	RESULTS	59
5.1	History and visual symptoms (I-V)	59
5.2	Ophthalmological findings (I-V)	59
5.2.1	Visual acuity	59
5.2.2	Alignment, motility and pupillary reactions	60
5.2.3	Biomicroscopy	60
5.2.4	Intraocular pressure	61
5.2.5	Ophthalmoscopy	61
5.3	Visual fields (I, II, V)	61
5.3.1	Kinetic perimetry (I, II, V)	61
5.3.1.1	Risk factors for visual field defects	63
5.3.1.2	Prognosis of visual field defects	64
5.3.2	Static perimetry (V)	65
5.4	Contrast sensitivity (III, V)	66
5.5	Glare sensitivity (III)	67
5.6	Color vision (IV, V)	67
5.6.1	Standard Pseudoisochromatic Plates 2	68
5.6.2	Farnsworth-Munsell 100 Hue test	68
5.6.3	Color Vision Meter 712 anomaloscope	70
5.7	Dark adaptation (III)	70
5.8	Electroretinogram (I)	71
5.9	Neuroradiology (I)	71
6	DISCUSSION	72
6.1	Patients and controls	72
6.2	Ophthalmological findings	73
6.3	Visual fields	74
6.3.1	General aspects	74
6.3.2	Methodology	75
6.3.3	Risk factors for visual field defects	76
6.3.4	Prognosis of visual field defects	77
6.4	Contrast sensitivity	78

6.5 Glare sensitivity 79

6.6 Color vision 79

6.7 Dark adaptation 80

6.8 Electroretinogram 81

6.9 Possible explanations for the vigabatrin-associated visual dysfunction 81

6.10 Implications for clinical practice 83

6.11 Future studies 85

7 CONCLUSIONS 86

8 REFERENCES 87

9 ORIGINAL PUBLICATIONS 104

1 INTRODUCTION

Epilepsy is a common neurological disease characterized by recurrent, usually unprovoked seizures due to excessive discharge of cerebral neurons. Around 10% of the population will experience a seizure at some time and about 1% of the population has epilepsy (Keränen et al., 1997). The majority of epilepsy patients needs long-term antiepileptic drug (AED) therapy in some phases of their life. A number of new AEDs have entered the market in recent years as a result of rational drug development. Potentiating the action of the main inhibitory neurotransmitter gamma-amino butyric acid (GABA) is one of the mechanisms of action of these drugs (Macdonald and Kelly, 1994). Vigabatrin (VGB) and tiagabine (TGB) are two drugs of the new generation of AEDs, both of which exert their pharmacological effects via the GABAergic system. They both are approved for the adjunctive management of partial epilepsy, and in addition, VGB is approved for the initial management of infantile spasms.

Until the appearance of the first reports about visual field defects associated with VGB therapy (Eke et al., 1997), VGB had a reputation for good efficacy and excellent tolerability (Marson et al., 1997). During the clinical development, only rare cases (less than 1:1000) of symptomatic visual field constrictions and retinal disorders were reported in association with VGB treatment. Between 1997 and 1998, symptomatic and asymptomatic concentric visual field constrictions and electrophysiological changes suggestive of retinal toxicity were reported in several case reports mostly of drug-resistant epilepsy patients receiving VGB concurrently with other AEDs (Krämer et al., 1997, Wilson and Brodie, 1997, Wong et al., 1997, Krauss et al., 1998, Leach et al., 1998, MacKenzie and Klistoner, 1998, Ruether et al., 1998). The prevalence rates for VGB-associated visual field defects varied from about 30% to 50% (Daneshvar et al., 1999, Lawden et al., 1999, Wild et al., 1999, Hardus et al., 2000a).

The exact mechanism of visual field defects associated with the use of VGB is not known, and on the basis of their GABAergic mechanism of action, the question has been raised whether TGB and other GABAergic AEDs cause visual field loss in a similar manner to that of VGB (Beran et al., 1998, 1999).

In the present study, the causal relationship between concentric visual field defects and VGB treatment, and the prevalence and prognosis of visual field defects were assessed in epilepsy patients treated with initial long-term VGB monotherapy, thus avoiding the confounding effect of AED polypharmacy. Another aim of the study was to evaluate the effect of VGB, TGB and carbamazepine

(CBZ) on visual function as many established and new AEDs have been found to affect color vision, contrast sensitivity and glare sensitivity (Bayer, 1991, Bayer et al., 1995a,b, 1997, Steinhoff et al., 1997a,b).

2 REVIEW OF THE LITERATURE

2.1 Anatomy and physiology of the retina

2.1.1 Overview

The principal function of the retina is to transduce the light from the outside world into neural signals, and to process and transmit these signals in a language usable by the brain. The outer part of the retina comprises a single layer of retinal pigment epithelium (RPE) cells which supply the metabolic needs of the neural retina. The neurosensory retina consists of neural, glial and vascular elements.

In the light microscopy, the neural retina may be subdivided into nine horizontal layers (Figure 1). It is composed of three layers of nerve cell bodies and two layers of synapses. The outer nuclear layer (ONL) contains cell bodies of the rods and cones, the inner nuclear layer (INL) contains cell bodies of bipolar, horizontal and amacrine cells, and the ganglion cell layer (GCL) contains cell bodies of ganglion cells and displaced amacrine cells. These nerve cell layers are divided by two plexiform layers which contain the functional synapses. In the outer plexiform layer (OPL), there are connections between photoreceptors and vertically running bipolar cells and horizontally oriented horizontal cells. The inner plexiform layer (IPL) connects bipolar cells and amacrine cells to ganglion cells. The non-myelinated axons of ganglion cells comprise the nerve fiber layer of the retina (Kolb, 1991a).

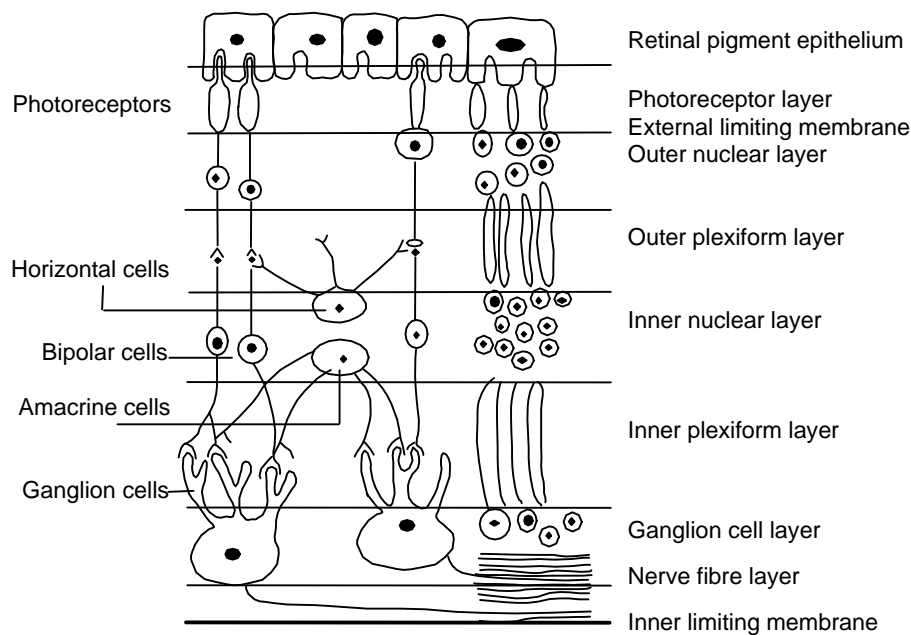


Figure 1. The layers and cells of the retina.

The second order neurons, bipolar cells, connect photoreceptors to the third order neurons, ganglion cells. In human retina, nine different bipolar cell types are revealed by Golgi staining, eight for cones and one for rods (Kolb, 1991a). The cone bipolar cells can synapse directly between photoreceptors and ganglion cells while the rod bipolar cells synapse with various amacrine cell types but not directly with ganglion cell dendrites. This allows both convergence and divergence of signals before synaptic output to ganglion cells.

Three different horizontal cell types make neural connections from photoreceptors to photoreceptors and to bipolar cells in the OPL. Horizontal cells send mainly inhibitory information back to cones and rods, and forward to bipolar cells. They are thought to be involved with the spatial and spectral center-surround antagonism of the retina, and thus to affect both contrast sensitivity and color vision (Perlman and Normann, 1990, Kolb, 1991a,b).

Amacrine cells interact at the second synaptic level (IPL) modulating the visual signal from the cones and rods to the ganglion cells. On the basis of their Golgi staining properties, intracellular recordings, immunocytochemical staining and electron microscopic findings, at least 25 different amacrine cell types have been identified in human retina (Kolb, 1991a). Most vertebrate amacrine cells are found to be inhibitory and, like horizontal cells, they interact with the spectral and spatial antagonism (Falk, 1991). Interplexiform cells are a subgroup of retinal cells which connect outer and inner plexiform layers (Kolb, 1991a).

Ganglion cells receive output from bipolar cells modulated by negative feedback from amacrine cells. Approximately 20 different ganglion cell types have been distinguished, but two of them are the most dominating (Kolb, 1991a). The small cell system responds tonically and conducts slowly, and mediates the visual acuity and color vision and projects to the parvocellular layers of the lateral geniculate nucleus. The large cell system responds phasically and quickly and mediates peripheral visual function and movement detection, and projects to the magnocellular layer of lateral geniculate nucleus (Kolb, 1991a,b).

Three different glial cells can be identified in the human retina. The principal glial cells, Müller cells, stretch through the whole thickness of the neural retina and provide structural support and nutrition for it. Müller cells protect neurons from exposure to excess neurotransmitters, using uptake mechanisms to recycle neurotransmitters such as glutamate and GABA (Napper and Kalloniatis, 1995). The role of other glial cells, astrocytes and microglia is mostly architectural support of vascular and neural tissues of the retina. Their possible metabolic properties have not yet been established.

2.1.2 GABA and GABAergic cells in the retina

Retinal neurotransmitters produce either excitatory (glutamate and acetylcholine) or inhibitory (GABA and glycine) effects by regional hyperpolarisation or depolarisation in the postsynaptic target neuron. GABA is the major inhibitory neurotransmitter in the central nervous system (CNS) and retina, and plays an important role in processing visual information. In rabbit retina, GABA has been localized into the OPL, INL, IPL and GCL (Ehinger, 1970, Perez and Davanger, 1994, Crook and Pow, 1997). In humans, GABA-immunoreactivity has been found in amacrine, bipolar and interplexiform cells in the INL, and in displaced amacrine cells in the GCL (Crooks and Kolb, 1992, Van Haesendonck and Missotten, 1993). Approximately 40% of the amacrine cells in human retina are found to be immunoreactive for GABA (Crooks and Kolb, 1992). The GABAergic feedback from amacrine to bipolar cells probably control bipolar cell output to ganglion cells.

GABA is synthesized in the presynaptic cell terminal from glutamate by the enzyme glutamic acid decarboxylase (GAD) and metabolized to succinate by GABA-transaminase (GABA-T) and succinic semi-aldehyde dehydrogenase in presynaptic neurons and glial cells (Figure 2). GABA inhibits neuronal firing via the receptors present on the postsynaptic cell membrane by opening Cl⁻ channels, resulting in a reduction of neuronal excitability. Three types of GABA receptors, GABA_A, GABA_B and GABA_C, with numerous subunits, have been characterized on the basis of their pharmacological and electrophysiological properties (Feigenspan and Bormann, 1998). Both GABA_A and GABA_C receptors gate chloride-selective ion channels, but their pharmacological properties differ markedly. GABA_C receptors are highly enriched in the mammalian retina, and they are found exclusively in the axon terminals of bipolar cells in IPL, where they coexist with the GABA_A receptors (Enz et al., 1996, Feigenspan and Bormann, 1998, Euler and Wässle, 1998). GABA_C receptors are enriched more in rod than in cone bipolar axon terminals. They are 10 times more sensitive than GABA_A receptors (Enz et al. 1996), and are responsible for small but sustained responses, while GABA_A receptors respond rapidly and more powerfully to brief stimulation (Feigenspan and Bormann, 1998, Euler and Wässle, 1998). GABA_A receptors have been identified in rodents in amacrine, bipolar, horizontal and ganglion cells (Hu et al., 1998, Feigenspan and Bormann, 1998, Euler and Wässle, 1998). GABA_B receptors interact via gating K⁺ and Ca²⁺ channels and have been shown to affect visual signal processing in amphibians (Slaughter and Tian, 1993, Arnarsson and Eysteinnsson, 1997) and in rabbits (Zucker and Paryani, 1998), but the role of GABA_B receptors in the human retina has not yet been resolved.

The activity of GABA is terminated by uptake into nerve cell terminals and glial cells by specific, high-affinity transporters (GAT). In rodent retina, three of these transporters, GAT1, GAT2, and GAT3 have been demonstrated in nerve cell processes in the IPL and in amacrine and Müller cells in INL (Ruiz et al., 1994, Hu et al., 1999).

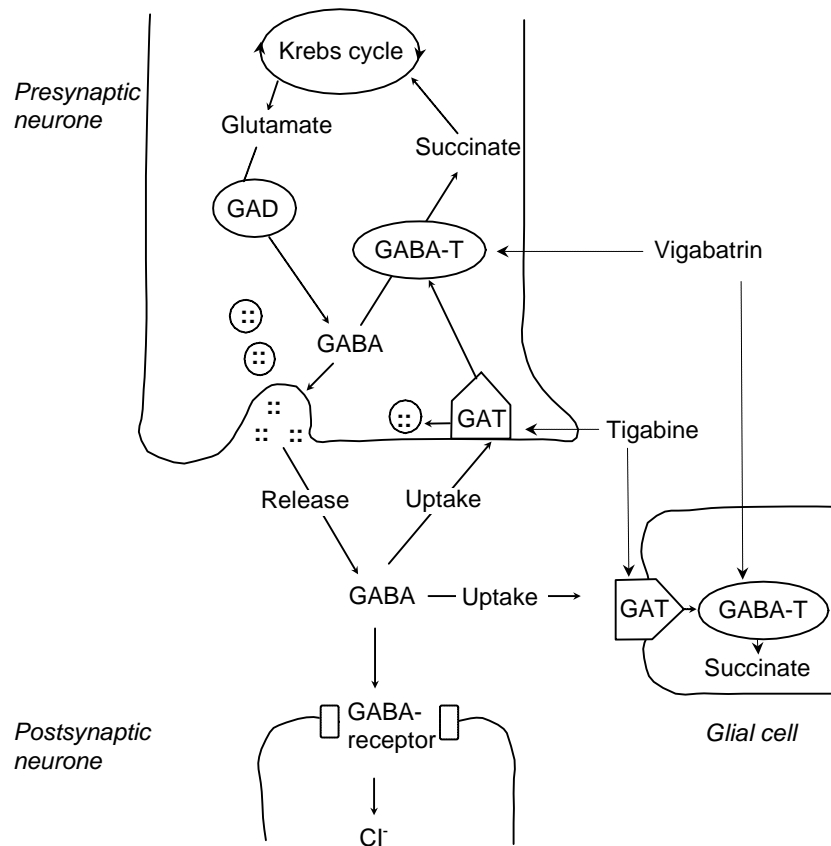


Figure 2. A diagram of a GABAergic synapse and the sites of action of vigabatrin and tiagabine (Leach and Brodie, 1998). (GABA = gamma-amino butyric acid, GABA-T = GABA-transaminase, GAD = glutamic acid decarboxylase, GAT = GABA-transporter).

2.2 Visual function tests

2.2.1 Overview

Visual function tests are used to gain information from several levels of the above described neuronal network and visual signal transduction in vivo (Table 1). However, the final establishment of the

visual perception takes place in the visual cortex after a modulation in the lateral geniculate nucleus. The following section deals with those tests which are used in the present series of studies.

Table 1. Visual function tests.

Test	Measuring the principal function of
Visual acuity	Foveal cone photoreceptors
Visual field	Photoreceptors, retinal network and visual pathways
Color vision	Foveal cone photoreceptors (photopigments) and retinal network
Contrast sensitivity	Photoreceptors and retinal network
Glare sensitivity	Photoreceptors
Dark adaptation	Photoreceptors and retinal network
Visual evoked potentials (VEP)	Visual pathways
Electroretinogram (ERG)	
a-wave	Photoreceptors
b-wave	Müller and bipolar cells
Oscillatory potentials	Amacrine cells
Electro-oculogram (EOG)	Photoreceptors and retinal pigment epithelium

2.2.2 Visual fields

Visual field examination is essential in the diagnosis of many ophthalmic and neurological disorders. The normal visual field extends about 100° temporally, 60° nasally, 60° superiorly and 75° inferiorly (Anderson, 1987). The contours of the visual field can be surveyed in two ways, by kinetic and by static perimetry.

In the kinetic perimetry, the boundaries of the visual field are measured by the operator with moving stimulus with different light intensity and spot size, and it is ideally suited for examination of the peripheral visual field. Peripheral retina is specialized for the detection of moving stimuli which is a benefit in this method.

The reliability of the kinetic perimetry depends on the examiner's skills. He or she continuously interacts with the patient and assess the reliability of the testing. This is a benefit in children and patients with slow reaction time, as the examiner can change the speed with which the stimulus is moved. However, this is not always advantageous as the speed of the stimulus may also influence the extent of the measured field. Fixation losses are not documented quantitatively but unreliable or contradictory answers can quickly be checked again by catch trials. The reliability of kinetic perimetry

has also been criticized on the grounds that the operator might consciously or unconsciously attempt to obtain a “correct” field which may cause a bias in the results. However, in a comparison between kinetic and automated static perimetries in normal controls, glaucoma patients and neurologic patients, Beck et al. (1985) found that only 2% of Goldmann visual field tests were unreliable, whereas 9% of the Humphrey results were inadequate, although both instruments were found to be sensitive and accurate in detecting visual field defects.

In computerized static perimetry, thresholds of 75-80 points arrayed in a regular grid pattern within 30° radius of the visual field are determined. The full threshold strategy determines the precise height and shape of the hill of vision, and it has been found to be efficient in detecting a decrease in visual sensitivity in the central retina, for instance in glaucoma patients, but it has also been used successfully in the diagnosis of neuro-ophthalmic diseases (Schindler and McCrary, 1981, Keltner and Johnson, 1983, Beck et al., 1985). Due to the limited spatial extent, however, the examination of the central 30° radius of the visual field may not reveal mild to moderate visual field losses in the periphery. The full threshold strategy for the visual field within 60° radius is particularly time consuming and demanding for the subject. In the suprathreshold or screening strategies, the stimulus is presented 6 dB brighter than the expected age-dependent threshold of each point (Humphrey Field Analyser II, HFA II, User’s Guide, 1998). According to this strategy, larger areas, i.e. 120 points within 60° radius of visual field can be quickly examined, but the screening strategy does not quantify threshold sensitivities.

Standardized stimulus characteristics, reliability criteria and statistical programs of automated perimetries help the detection of change in repeated visual field examinations. However, interpretation of the computerized static perimetry results may be adversely influenced by the physiological variability of the patient response during (short term fluctuation) or between (long term fluctuation) the examinations. A learning effect as well as a fatigue effect influence to the outcome of automated perimetry (Beck et al., 1985, Wild et al., 1991, Olsson et al., 1997).

Independent of the testing method used, the outcome of visual field tests must always be interpreted in the context of many patient-related factors. The visual acuity, age and cognitive capacity of the patient are the most important factors for obtaining reliable results in visual field examination (Egge, 1984). Generally, reliable assessment of visual fields in children over 9 years of developmental age is possible with perimetry (Appleton, 1998), especially with kinetic perimetry, but in a recent study by Morales and Brown (2001), short automated perimetry was found to be feasible in children over 7 year old. Reliable assessment of visual fields in young children and in people with

learning difficulties or poor concentration is seldom possible since all types of visual field tests require sustained concentration by the patient.

2.2.3 Contrast sensitivity

The measuring of contrast sensitivity, i.e. the minimal contrast required to detect the intensity difference between the luminance of the object and that of its surroundings, allows a more functional assessment of visual system than using a conventional visual acuity chart. For grating patterns, contrast is defined as the difference of maximal and minimal luminance divided by the sum of them (Michelson contrast). For letter contrast sensitivity charts, contrast is defined as the difference in luminance between the letter and its background, divided by the luminance of the background (Weber contrast). This value ranges from 0 to 1 and is usually multiplied by 100 to get a percentage contrast. The lowest detectable contrast is called the contrast threshold of the subject. The contrast sensitivity is defined as the reciprocal of the contrast threshold, i.e. $1/\text{contrast}$, ranging from 1 to infinity (Wolfe, 1990).

Contrast sensitivity tests measure the minimal contrast required to detect different spatial frequencies. The spatial frequency of a grating is the number of cycles (one black and one white bar) per degree of visual angle (cpd). The peak sensitivity is about 5 cpd and it falls off at higher and lower spatial frequencies. In clinical tests, contrast sensitivity value for either one (for instance, Pelli-Robson 1 or 3 cpd) or several (for instance, Vistech 1.5 to 18 cpd) spatial frequencies can be examined.

2.2.4 Glare sensitivity

The physiologic basis for glare sensitivity is the bleaching of the visual pigments in intense light and the resynthesis of the photosensitive pigments after the exposure of light. *The macular photostress test* is used in the differential diagnosis of macular diseases and optic neuropathies in patients with decreased visual acuity. Patients with macular disturbances have a prolonged recovery time from glare instead of the normal recovery time found in patients with optic neuropathies (Glaser et al., 1977). The effect of glare on visual perception can be measured with *the brightness acuity test (BAT)*, either in high contrast (visual acuity) or low contrast (contrast sensitivity) conditions (Prager,

1990). Impaired brightness acuity is commonly found in anterior eye diseases, such as cataract or corneal opacity.

2.2.5 Color vision

Many diseases in the retina and visual pathways, as well as toxic agents and drugs, can cause deterioration in color vision. Chromatic mechanisms are highly susceptible to incipient injuries, so that acquired color vision defects may be the first sign of ocular toxicity. Short wavelength cones are particularly vulnerable to acquired damage resulting in a blue (tritan) defect, but also red (protan) or green (deutan) defects can occur as a consequence of toxic injury (Hart, 1987).

Clinical color vision examination can be carried out in two stages. Plate tests such as Ishihara (1957), AO-HRR (Hardy et al., 1957) and Standard Pseudoisochromatic Plates Part 2 (SPP2, Ichikawa et al., 1983) answer only the question whether the patient has normal color vision or not, and only give a hint for the exact diagnosis. In the second stage, the definite diagnosis and the assessment of the severity of the defect can be done with the arrangement tests, for instance, Farnsworth-Munsell 100 Hue test (FM100, Farnsworth, 1957). The colored caps have to be arranged according to the hues. The score of each cap is calculated as the sum of the absolute differences between the adjacent caps. The total errors are usually converted as square roots and divided into blue-yellow and red-green partial scores (Kinnear, 1970). To calculate an axis, the square root of the red-green errors is subtracted from the square root of blue-yellow errors (Smith et al., 1985). The subject has a color vision defect if the error score is above the age-related upper limit (Verriest et al., 1982, Mäntyjärvi 2001) and/or if an axis (red, green or blue) can be found in the result diagram (Smith et al., 1985).

Using an anomaloscope we can examine the ability of the subject to equate a mixture of two monochromatic colors with a third comparison wavelength (Birch et al., 1979). In the Rayleigh equation, green (545 nm) and red (670 nm) primaries are mixed, and the mixture is compared to match with yellow (590 nm). In the Moreland equation, blue (436 nm) and green (490 nm) primaries are mixed, and the mixture is compared with cyan blue (480 nm + 580 nm). The scale of the instrument is divided into 100 units, 0 representing the green color and 100 the red color in the Rayleigh equation, and 0 in the scale representing the blue color and 100 the green color in the Moreland equation. The proportion of mixed primaries used to obtain a match is given as mid matching point (MMP), and the range of mixtures which will be accepted as matching the reference color is given as the matching range (MR) (Birch et al., 1979). Subjects with color vision defects do

not accept the normal MMP requiring an excess of red, green or blue color. This deviation from normality is expressed mathematically by the anomalous quotient (AQ). The AQs of normal trichromats fall between about 0.7 and 1.4 (Birch et al., 1979, Roth, 1984, Maaranen et al., 2000). The normal limits of MR vary from about 0 to 11 scale units (Roth, 1984, Maaranen et al., 2000).

2.3 Epilepsy and antiepileptic therapy with vigabatrin, tiagabine and carbamazepine

2.3.1 Epilepsy

Epilepsies are a group of symptom complexes arising from disordered brain functions that themselves may be secondary to a variety of pathologic processes, such as brain injuries, infections, neoplasms and vascular diseases. The common and fundamental characteristic of epilepsies are recurrent, usually unprovoked epileptic seizures. These, in turn, are a consequence of a sudden, excessive, synchronous, abnormal firing pattern of neurons in a part of the brain, predominantly in the cerebral cortex, producing alterations in consciousness, behavior, emotion, motor function or sensation as clinical manifestations (Engel and Pedley, 1997).

According to the Commission on Classification and Terminology of the International League Against Epilepsy (ILAE, 1989), the disorder of the brain may be apparently localized and known as “localization related” (partial), or generalized. Both localization related and generalized epilepsies and syndromes are divided according to the etiology into idiopathic and symptomatic varieties. Idiopathic epilepsies are not associated with brain lesions, neurological abnormalities other than seizures, or cognitive impairment. The onset of manifestations are typically age-related. Conversely, in remote symptomatic epilepsy, seizures are the consequence of a focal brain abnormality or other specific etiology. When epilepsies are probably remote symptomatic, but of unknown etiology, they are termed cryptogenic (Commission on Classification and Terminology of the ILAE, 1989).

Medical therapy is the standard treatment for the majority of epilepsy patients. The goal of the therapy is the cessation of seizures with as few adverse effects as possible. The therapy is long-term, even life-long, regular treatment with single (monotherapy) or several (add-on or polytherapy) drugs. Therapy is tailored according to the type of epilepsy (partial or generalized) (Kälviäinen et al., 1993, Keränen et al., 1997). There are no clear differences in efficacy between first line monotherapy AEDs for partial epilepsy such as carbamazepine (CBZ), phenytoin (DPH), valproate (VPA), lamotrigine and oxcarbazepine (Mattson et al., 1985, Mattson et al., 1992, Brodie et al., 1995, Bill et al., 1997), nor have the newer AEDs (gabapentin, levetiracetam, tiagabine (TGB), topiramate, vigabatrin (VGB) and zonisamide) shown significant difference in efficacy or tolerability in a meta-analysis of trials in

drug-resistant partial epilepsy (Chadwick et al., 1996, Marson and Chadwick, 2001). Therefore, the choice of an AED in the treatment of an individual patient is a compromise between efficacy and adverse effects. The withdrawal of AED therapy can be discussed with a patient suffering from partial epilepsy after the patient has been seizure free for 2 to 5 years (Keränen et al., 1997).

The AEDs available today can be divided into three categories in terms of their mechanisms of action (Macdonald and Kelly, 1994). Most commonly, the drugs affect the flow of sodium into the cell via voltage-gated sodium ion channels. A sodium ion channel is a structure in the cell membrane that is selectively permeable to sodium ions and is opened by changes in voltage across the cell membrane. Secondly, AEDs may affect calcium flow via voltage gated calcium ion channels. The third category of AEDs affect neurotransmitter receptors or neurotransmitter metabolism. The most widely used first-line standard AEDs for partial epilepsy have been DPH and CBZ, which share similar mechanisms of action, i.e., a voltage- and use-dependent block of voltage-sensitive sodium channels. Among the new drugs, VGB and TGB are unique in that they were derived from mechanistic-based drug discovery programs designed to identify effective AEDs that inhibit the metabolism and the uptake of the inhibitory neurotransmitter GABA, respectively.

2.3.2 Vigabatrin

Vigabatrin, gamma-vinyl-GABA, was synthesized in the 1970s and was used clinically for the first time in 1979. VGB is a structural analogue of GABA. It acts as a selective irreversible inhibitor of GABA-T, the metabolizing enzyme of the re-uptaken GABA in the neurons and glial cells (Figure 2). VGB increases GABA concentrations in the CNS of animals and humans and induces a dose-related increase in free and total GABA in the cerebrospinal fluid (CSF) (Schechter et al., 1977, Neal and Shah, 1990, Kälviäinen, 1992, Petroff et al., 1999). The anticonvulsant efficacy of VGB has been shown in animals and humans (Schechter et al., 1977, Kälviäinen et al., 1995, Marson et al., 1997, Cramer et al., 1999). The absorption of VGB from the gastrointestinal tract is rapid and almost complete. It is not protein-bound or metabolized, and it is excreted via the kidneys. The peak serum levels are attained within about 2 h and half-time of VGB is from 5 to 8h. VGB has been shown to be well tolerated in long-term use, the most frequently reported adverse effects being fatigue, headache, weight gain, depression, abnormal thinking and dizziness (Kälviäinen et al., 1995, Chadwick, 1999, Ylinen et al., 1999, Guberman et al., 2000). Diplopia and nystagmus are the reported ophthalmic adverse events in clinical trials (Cramer et al., 1999, Guberman et al., 2000). Despite rapid systemic elimination, the effect of VGB in the CNS is long-term both in animals and humans (Arteaga et al.,

1992, Valdizán et al., 1999). Screening of the plasma levels of VGB or other blood tests for safety reasons is not recommended during treatment (Commission on antiepileptic drugs of the ILAE, 1993, Tomson and Johannessen, 2000), although it has been shown that the levels of hepatic transaminases are markedly lowered during VGB therapy (Van Parys et al., 1995, Guberman et al., 2000). VGB is currently approved in over 65 countries world-wide for the adjunctive management of partial epilepsy, which is not satisfactorily controlled by conventional therapy, for initial monotherapy in the management of infantile spasms (West syndrome), and for seizures caused by tuberous sclerosis.

2.3.3 Tiagabine

Tiagabine, nipecotic acid hydrochloride, has a unique mode of action involving GABA. It is a potent, selective and specific inhibitor of both neuronal and glial presynaptic GABA uptake (Susztrak and Jansen, 1995) (Figure 2). It binds to a single class of high-affinity binding sites, probably the GABA transporter GAT-1 (Borden et al., 1994). Consequently, treatment with TGB leads to an increased synaptic content of GABA and to enhancement of GABAergic transmission in the brain, resulting in a cessation of seizures (Fink-Jensen et al., 1992, Morimoto et al., 1997, Dalby, 2000). TGB is rapidly absorbed from the gastrointestinal tract with peak concentrations seen within 30-90 minutes of dosing. Protein binding is high (96%), but because therapeutic plasma concentrations are in the nanomolar range TGB does not displace highly protein-bound drugs. TGB is widely metabolized in humans, mainly by the cytochrome P-450 enzyme CYP3A, less than 1% is excreted unchanged in the urine, and no active metabolites have been identified (Leach and Brodie, 1998). The efficacy and safety of TGB in the treatment of partial epilepsy have been shown in several studies (Kälviäinen et al., 1998, Leppik et al., 1999, Loiseau, 1999, Fakhoury et al., 2000a). The antiepileptic and adverse effects of TGB are more strongly related to the dose than to the plasma concentration, and there are no specific guidelines for routine monitoring of laboratory values or concentrations of TGB (Tomson and Johannessen, 2000). The most frequently reported adverse effects, such as dizziness, asthenia, nervousness and tremor, are related to the CNS (Kälviäinen et al., 1998, Leppik et al., 1999). In clinical trials of 494 patients treated with TGB, no ophthalmic adverse events were reported (Cramer et al., 1999). TGB is registered in over 20 countries for the adjunctive treatment of adults and children over 12 years with partial seizures with or without secondary generalization.

2.3.4 Carbamazepine

Carbamazepine (CBZ) is a derivative of iminostilbene and is chemically related to tricyclic antidepressants. It is an established first-line AED in the management of partial seizures with or without generalization (Mattson et al., 1985, 1992, Keränen et al., 1997). Its principal mechanism of action is to inhibit high-frequency neuronal firing of action potentials by blocking the voltage-gated sodium channel (Macdonald and Kelly, 1994). The most common adverse effects of CBZ are fatigue, diplopia, headache, dizziness, nausea, nystagmus and idiosyncratic skin reactions (Mattson, 1998, Cramer et al., 1999). Screening the plasma levels of CBZ is routine in monitoring the therapeutic response and neurotoxic effects of the drug (Commission on antiepileptic drugs of the ILAE, 1993). The suggested reference values for CBZ range from 20 to 50 $\mu\text{mol/l}$. However, these ranges can be ignored if the patient is seizure-free and untroubled by symptoms of toxicity.

2.4. The influence of vigabatrin on the visual system

2.4.1 Retina and visual pathways

The preclinical toxicity studies of VGB showed changes in the retinas of albino (Sprague-Dawley) rats, but not of pigmented (Lister-Hooded) rats (Butler et al., 1987). The changes in electron microscope studies consisted of a disorganization of the ONL with displacement of the nuclei into the rod layer affecting most the periphery of the retina. No other retinal layers or optic nerve were affected. Histologically similar retinopathy was found earlier in albino rats during excessive exposure to light, and it was suggested that the changes were caused by the toxicity of the light in albino rats. In ophthalmoscopy or microscopic examination of the retinas after VGB exposure, no drug-associated retinopathy has been observed in dogs or monkeys (Gibson et al., 1990).

The effects of VGB on retinal GABA have been studied in animal experiments with immunocytochemical methods (Neal et al., 1989). GABA-immunoreactivity was observed in the amacrine cell bodies, glial Müller cells and IPL of VGB treated animals. The authors suggested that the administration of VGB might cause the accumulation of GABA in retinal cells that do not normally possess enough endogenous GABA to be detected by immunochemistry. After subcutaneous injection of VGB 50mg/kg and 100mg/kg, retinal GABA levels increased two fold to levels significantly higher than those in control rats ($p < 0.0001$) (Cubells et al., 1987). In two studies by Neal et al. (1989 and 1990), acute intraperitoneal administration of VGB 250mg/kg to rats reduced retinal GABA-T activity by 98% and increased the retinal GABA content 5-to-6-fold.

Corresponding rates in the cerebral cortex were 80% and 2-fold, respectively. However, the increase in GABA content in the retina was reduced by approximately 40% during chronic treatment of 250mg/kg VGB for 17 days (Neal and Shah, 1990). Active transport and accumulation of immunolabelled VGB in the amacrine cells and Müller cells in the retina of rabbits, cats and monkeys have been detected with both light and electron microscopes (Pow et al., 1996, Crook and Pow, 1997). Neither horizontal nor ganglion cells accumulate VGB in any species. It has been suggested that long-term GABA-T inhibition with VGB may cause an accumulation of GABA in the Müller cells at a rate that may exceed the rate of catabolism by these cells (Neal et al., 1989).

Recently, it has been shown in rats that VGB treatment is associated with dose-related decreases in the activity of GABA-T, and a consecutive rise in GABA levels in various brain regions, but this effect was found to be more pronounced in retina (Sills et al., 2001). In addition, it was found that VGB concentrations, although dose-related, were significantly higher in the retina than in the other tissues investigated (Sills et al., 2001).

The first concern about the toxic effects of VGB on the visual pathways arose during the development of VGB, when drug-induced local microvacuolation of the white matter, or intramyelinic edema, was found in animals (Butler et al., 1987, Butler, 1989). The dose-related reversible microvacuolation occurred at the hippocampus, cerebellum, reticular formation, optic tracts and the columns of the fornix in rats and dogs, but not in monkeys (Gibson et al., 1990). Histologically, the vacuolation was caused by myelin separation, and there was no evidence of demyelination or damage in the neuronal cell bodies or nerve fibers. In addition to microvacuolation, reactive astrocytosis and microglial activation were observed. The retina, optic nerve, spinal cord and peripheral nerves were spared intact. Microvacuols in the white matter were reversible in all species after cessation of VGB.

In humans, no microvacuolation or other drug-associated pathology have been found in neuropathologic examinations in patients with long-term VGB treatment (Butler 1989, Cannon et al., 1991a,b, Sivenius et al., 1993, Cohen et al., 2000).

The only report of histopathological changes in the anterior visual pathways in an epilepsy patient with a documented VGB-associated visual field defect has been recently reported by Ravindran et al. (2001). The patient died from cardio-pulmonary arrest after visual field defects were detected and documented. Histology of the retina showed severe atrophy of the peripheral retina and less severe involvement of the macula. There was loss of ganglion cells and partial loss of nuclei from the INL and ONL. The optic nerves and tracts showed severe atrophy mainly in the peripheral retinal fibers but no microvacuolation was observed.

Individual case reports of patients with optic neuropathy have been reported during the therapeutic use of VGB (Dieterle et al., 1994, Crofts et al., 1997, Buncic et. al., 2001). In these patients, visual acuity as well as VEP latencies and amplitudes were decreased, indicating that the optic nerve had been affected. Systemic cortisone therapy had favorable effects, but optic nerve atrophy and concentric constriction of visual fields were observed later.

2.4.2 Visual fields

The diminishing size of the hill of vision, or concentric constriction of the visual field is a common finding in many tapetoretinal dystrophies (Carr and Heckenlively, 1996). Furthermore, some toxic agents and drugs, for instance chloroquine and quinine, may affect the retina or optic nerve, producing concentric constriction of visual fields in addition to impaired visual acuity and retinal changes (Lowes, 1976, Brinton et al., 1980, Danias and Brodie, 2001). Reports of visual field constrictions associated with epileptic seizures (Trojan 1967) or AED therapy other than VGB (Zrenner and Nowicki, 1985, Lorenz and Kuck, 1988, Bayer, 1991, Elder, 1992, Schmidt et al., 1999, Schmitz et al., 1999, Malmgren et al., 2001) have been published, infrequently. Visual field defects noticed during these AED therapies are mostly considered to be a consequence of intoxication or over-dosage, and usually they are resolved by dose reduction (Zrenner and Nowicki, 1985, Lorenz and Kuck, 1988, Bayer, 1991, Elder, 1992). The problem in this context is that epilepsy occurs in association with many underlying CNS abnormalities (Meldrum, 1990). In symptomatic epilepsy, visual pathways and the occipital cortex may be affected, producing visual field defects which usually correspond to anatomical changes visible in CT or MRI.

During the development of VGB, only rare cases (less than 1 per 1000 patients treated) of symptomatic visual field constriction and retinal disorders have been reported to the manufacturer. In the early 1990s, sporadic reports of bilateral concentric visual field constriction in association with VGB therapy were published (Bayer, 1991, Faedda et al., 1993). In the academic thesis by Bayer (1991), six of eight patients who received VGB as add-on therapy with DPH had concentrically constricted visual fields when examined with Octopus automated perimetry. At that time, the causative role of VGB was not suspected, as in this particular study six of eleven patients treated with DPH monotherapy had similar defects in their visual fields; this led the author to conclude that DPH intoxication was the probable cause of these findings.

The potential seriousness of VGB-attributed visual field loss was exposed in 1997 after case reports by Eke et al. (1997). They described three patients aged 22 to 46 years who had severe persistent visual field constriction with subnormal ERGs and EOGs after treatment with VGB for 2 to 3 years. The debate this provoked also resulted in the presentation of additional cases with similar visual field losses in epilepsy patients who received VGB (Blackwell et al., 1997, Harding, 1997, Krämer et al., 1997, Wilson and Brodie, 1997, Wong et al., 1997, Beran et al., 1998, Krauss et al., 1998, Leach et al., 1998, MacKenzie and Klistorner, 1998, Ruether et al., 1998, Bjelajac et al., 1999). However, short-term VGB exposure as a single-dose of 3g (Tiel-Wilck et al., 1995) or for a period of 10 days with an increasing dose of 1 to 2 g (Harding et al., 1999) did not affect kinetic or static perimeter assessment of visual fields in healthy volunteers.

2.4.2.1 Characteristics of VGB-associated visual field defects

The VGB-associated visual field defect is unique and specific in nature. In kinetic perimetry, it is typically a bilateral, absolute concentric constriction of the visual field, the severity of which varies from mild to severe (Eke et al., 1997, Miller et al., 1999, Hardus et al., 2000a). In automated perimetry, within a 30° radius from fixation, it shows as a nasal loss extending in an annulus over the horizontal midline, with a relative sparing of the temporal field (Lawden et al., 1999, Wild et al., 1999, Manuchehri et al., 2000). In the most severe cases, the visual field defect is concentric also with static perimetry. However, nasal preponderance was not found by Hardus et al. (2000a) with static or kinetic perimetry in a series of 157 patients. Schiefer et al. (2000) examined 109 VGB patients with static Octopus perimetry using three-zone suprathreshold strategy where the entire 90° field can be examined, and found that the majority of defects did not affect the central 30° of the visual field even when relative losses were taken into account. Nasal preference was found only if absolute defect was considered. This discrepancy in the features of VGB-associated visual field defect is probably based on the methodological differences between visual field examinations.

The lack of valid age-related normal values for kinetic visual field tests has confounded the definition of VGB-associated visual field defect in different studies. Generally, kinetic visual fields extending over 70° temporally, 40° superiorly, 45° nasally and 50° inferiorly measured with the Goldmann stimulus I/4 have been considered as normal (Galán, 1968, Egge, 1984, Wild et al., 1999). In their evaluation of kinetic perimetries, Hardus et al. (2000a,b, 2001a) used standardized Esterman grid scores where the total number of not-seen points was calculated. Esterman grid consists of 100

points, and the missing of one point represents a visual field loss of 1%. The disadvantage of the Esterman method is that the dots are distributed unequally over the four quadrants and that the points are missing in the far periphery (Hardus et al., 2001a). More recently, Hardus et al. (2001a) developed a new method to calculate the concentric constriction of the visual fields by surface-measuring method and compared the results with those of normal controls. In the studies by Miller et al. (1999) and Johnson et al. (2000), the mean radius of the visual field extents based on the Diabetic Retinopathy Study Protocol was used. In addition, the area of the visual field has been measured planimetrically (Schmitz et al., 1999).

In studies reporting automated perimetry results using 30o threshold strategy, the mean deviation from age-corrected normals has been the main outcome measure (Arndt et al., 1999a, Daneshvar et al., 1999, Lawden et al., 1999, Miller et al., 1999, Wild et al., 1999, Paul et al., 2001). There are no normative values for the threshold strategy of the periphery from 30o to 60o, and this has limited its usefulness in evaluations of VGB-associated visual field defect (Daneshvar et al., 1999, Lawden et al., 1999). In studies where automated screening tests are used, results of normal controls (Midelfart et al., 2000) or epilepsy patients without VGB medication (Manuchehri et al., 2000) have been used as a reference. In statistical analyzes of kinetic or static visual fields, both age-matched normal controls (Daneshvar et al., 1999, Wild et al., 1999, Midelfart et al., 2000, Hardus et al., 2001a) and epilepsy patients without VGB therapy (Miller et al., 1999, Manuchehri et al., 2000) have been used as a reference.

In all types of visual field examination, a large number of more or less well-controlled variables interfere with the results, including patient compliance and/or possible fatigue as well as the skills of the perimetrist. Pre-existent visual field defects associated with the epilepsy or with the background brain pathology may cause false positive findings but, on the other hand, worsening of the pre-existing defect can also be overlooked. Automated threshold perimetry has been suggested for its superior standardization in screening epilepsy patients taking VGB, but it is too demanding for some epilepsy patient, and sometimes less demanding kinetic or confrontation perimetry is the only feasible visual field test that can be carried out.

2.4.2.2 Symptoms

Although the majority of the patients with VGB-associated visual field defects have been asymptomatic (MacKenzie and Klistoner, 1998, Rao et al., 1998, Daneshvar et al., 1999, Wild et al., 1999, Hardus et al., 2000a and 2001a, Gross-Tsur et al., 2000, Iannetti et al., 2000), there have been also symptomatic cases. Patients have complained about blurred vision, oscillopsia, tunnel vision and difficulties in movement, for instance bumping into objects (Blackwell et al., 1997, Eke, 1997, Wilson and Brodie, 1997, Wong et al., 1997, Krauss et al., 1998, Ruether et al., 1998, Arndt et al., 1999a, Lawden et al., 1999, Manuchehri et al., 2000). In a minority of patients the defect was so severe that it limited their ability to perform a variety of activities of daily living. Some of the patients had not realized that their symptoms were of visual origin, but had thought that they were caused by clumsiness or drowsiness. This increased the number of patients, who were initially asymptomatic and only realized the cause of their problems after formal visual field examination.

The difficulty in recognizing the symptoms has obviously also led to the exceptional delay in observing this common adverse effect of VGB. For example, Wilton et al. (1999) have published an observational cohort study based to a prescription event monitoring study covering the period from 1991 to 1994 with an extended follow-up from 1998 to 1999. They revealed an incidence risk of possible or probable VGB-associated visual field constriction of 7.0 per 1000 patients (33 affected of 4741 patients). However, this evaluation was done via questionnaires sent to physicians, the main question being whether any serious adverse events or changes in vision had been reported. As current data clearly indicate that the VGB-associated visual field constriction is asymptomatic until gross field loss has occurred, most probably the unrecognized symptoms caused serious underestimation of the risk in that study.

2.4.2.3 Prevalence of vigabatrin-associated visual field defects

Systematic evaluations have shown variable prevalence rates for visual field constriction, as no consensus has yet been reached either on the best method of visual field testing or on the unified criteria for the presence of concentric visual field defects. The Marketing Authorization Holders provided 1999 data from a pooled cohort of 335 VGB recipients aged over 14 years, all evaluated by the same expert (Committee for Proprietary Medicinal Products, CPMP-report/1357/99). Of these, 31% (95% confidence interval (CI) 26% to 36%) manifested a VGB-attributed visual field defect; this compared with a 0% (upper 95% CI 3%) in an unexposed control cohort. The published data relating to adult study populations by different investigators give a similar overall prevalence, with 330 of 836 patients diagnosed with VGB-associated defects (39%, 95% CI 36% to 42%) (Table 2).

Table 2. Prevalence of VGB-associated visual field defects in adults in published studies.

Study	Overall prevalence	Male prevalence	Female prevalence
Arndt et al., 1999a	11/19 (58%)	8/10 (80%)	3/9 (33%)
Daneshvar et al., 1999	12/41 (29%)	not stated	not stated
Hardus et al., 2000a	20/118 (17%)	15/72 (21%)	5/85 (6%)
Lawden et al., 1999	12/31 (39%)	not stated	not stated
Malmgren et al., 2001	19/99 (19%)	not stated	not stated
Manuchehri et al., 2000	11/20 (55%)	8/12 (67%)	3/8 (38%)
Midelfart et al., 2000	15/18 (83%)	9/9 (100%)	6/9 (67%)
Miller et al., 1999	8/20 (40%)	not stated	not stated
Newman et al., 2000	119/142 (84%)	not stated	not stated
Rebolleda et al., 2000	5/10 (50%)	not stated	not stated
Schiefer et al., 2000	32/109 (29%)	not stated	not stated
Specchio et al., 2000	28/41 (68%)	not stated	not stated
Stefan et al., 1999	9/69 (13%)	not stated	not stated
Wild et al., 1999	29/99 (29%)	17/45 (38%)	12/54 (22%)
Total	330/836 (39%) (95% CI 36%-42%)	57 /148 (39%) (95% CI 31-47%)	29/165 (18%) (95%CI 12-24%)

2.4.2.4 Risk factors for vigabatrin-associated visual field defects

The duration of VGB therapy before the occurrence of the visual field defect has varied considerably. In different studies, VGB therapy has been continued for from six weeks to 180 months before the visual field loss has been diagnosed (Eke et al., 1997, Arndt et al., 1999a, Daneshvar et al., 1999, Lawden et al., 1999, Miller et al., 1999, Schmitz et al., 1999, Wild et al., 1999, Wohlrab et al., 1999, Manuchehri et al., 2000, Midelfart et al., 2000, Rebolleda et al., 2000, Hardus et al., 2000a, 2001a). The cumulative prevalence seems to reach a maximum at about 3 to 4 years, after which it plateaus. An evaluation of a cohort of epilepsy patients exposed to VGB (Wild et al., 1999) revealed a prevalence rate for visual field defects of 32% (95% CI 17%-47%) in patients who had received VGB for less than 4 years (12 of 39) and 28% (95% CI 17%-39%) in those who had received vigabatrin for over 4 years (17 of 61). In a cohort of 155 epilepsy surgery candidates, a visual field defect was found in 19 out of 99 (19%) patients who were exposed to VGB before the examination (Malmgren et al., 2001). The VGB recipients who had visual field defects, had been treated with VGB significantly longer (52 months) than those who had no defects (14.6 months, $p < 0.001$). In another study on epilepsy surgery candidates (Hardus et al., 2000a), the loss of visual fields was significantly more extensive in patients who had used VGB for 2-4 years or 4-6 years than in patients who had used VGB for 0-2 years.

The correlation between the daily or cumulative dose of VGB and the risk of visual field defects has been investigated in several studies. Wild et al. (1999) did not find any correlation, while Manuchehri et al. (2000) showed that a significant correlation ($p = 0.002$) existed between the severity of the visual field defect and the total dose ingested. Moreover, it has been found that the total amount of ingested VGB is the most significant parameter to predict visual field loss (Hardus et al., 2001a, Malmgren et al., 2001). The association between the cumulative incidence of visual field defect and cumulative dose has also been evaluated by the Marketing Authorization Holders in a cohort of 291 patients (CPMP-report/1999); the prevalence of visual field defects in this cohort was 30.2%. A steep increase in the cumulative incidence was found within the first 2 kg of VGB intake. Incidence appeared to plateau after a total of 3kg of VGB intake (i.e. 3g/day for 3 years).

Male gender has been associated with an increased risk for VGB-associated visual field defects in several studies (Wild et al., 1999, Hardus et al., 2000a, 2001a). In the Marketing Authorization Holders cohort, a positive association was found for male gender, with a cumulative incidence ratio of 1.9 (CI 1.4-2.7) (CPMP-report/1999). The prevalence of visual field defects in either gender is stated in 5 of the published studies in adult epilepsy patients. A clear risk for male gender can be

found on the basis of these data; visual field defects were found in 57 of 148 males (39%, 95% CI 31% to 47%) compared with 29 of 165 females (18%, 95% CI 12% to 24%), (Table 2).

2.4.2.5 Visual field defects in children treated with vigabatrin

In pediatric patients, the criteria for concentric visual field defect are even more confusing than in adults. Both kinetic and static perimetries have been examined in cooperative patients but no clear definition for abnormality have been presented (Wohlrab et al., 1999, Gross-Tsur et al., 2000, Iannetti et al., 2000, Luchetti et al., 2000, Russell-Eggitt et al., 2000). The method used may vary even within one study (Gross-Tsur et al., 2000). Although there are studies concerning the normality of visual fields in children (Whiteside, 1976, Myers et al., 1999), the developmental age and possible neurological and psychological conditions of the pediatric epilepsy patients have to be taken into account in the interpretation of perimetry results. As there are always children who cannot perform perimetry reliably, the study population is always more or less selected. It has even been speculated that the use of VGB in children and adolescents might have a lower risk for visual field defects (Rintahaka et al., 2000).

The prevalence rates in the pediatric series are presented in Table 3. In addition, three pediatric case reports with VGB-associated visual field defects have been published (Versino et al., 1999, Vanhatalo et al., 1999). There is no information on the possible occurrence of visual field defects in children who have been exposed to VGB in utero. During the development of the fetus, it has been suggested that GABA acts as a trophic agent in retinal maturation (Crook and Pow, 1997, Hu et al., 1998).

Table 3. Prevalence of VGB-associated visual field defects in pediatric patients.

Brigell et al., 2000	14/63 (22%)
Gross-Tsur et al., 2000	11/17 (65%)
Iannetti et al., 2000	4/21 (19%)
Luchetti et al., 2000	8/13 (62%)
Rintahaka et al., 2000	4/53 (8%)
Russell-Eggitt et al., 2000	10/14 (71%)
Vanhatalo et al. (Unpublished)	17/91 (19%)
Vecchio et al., 2000	2/8 (25%)
Wohlrab et al., 1999	5/12 (42%)
Total	75/292 (26%) (95% CI 21% - 31%)

2.4.2.6 Prognosis of vigabatrin-associated visual field defects

One of the criteria for a drug-induced adverse event is recovery upon withdrawal of the causative drug. Thus, the question has been raised whether visual field defects are reversible after cessation of the VGB therapy. The initial report by Eke et al. (1997) suggested that VGB-attributed visual field defects are not reversible, and most studies thus far support their claim (Wong et al., 1997, Ruether et al., 1998, Arndt et al., 1999b, Johnson et al., 2000, Harding et al., 2000b, Llerda et al., 2000, Schmidt et al., 2000, Paul et al., 2001, Malmgren et al., 2001). In a long-term evaluation of VGB-associated visual field loss, Hardus et al. (2000b) compared the visual field constriction in 16 patients who had already stopped VGB medication before the first examination with that in 11 patients who still continued VGB medication. In the follow-up, the concentric contraction did not change in this selected group of patients, suggesting that VGB-associated visual field loss is not reversible.

Five patients (two of whom were children) in four case reports have shown a recovery in visual field constriction after withdrawal of VGB (Versino et al., 1999, Iannetti et al., 2000, Giordano et al., 2000, Krakow et al., 2000). The authors suggested that young age may be a favorable factor in the recovery, as repair mechanisms for retinal damage are more efficient in young people than in adults. However, in the report by Versino et al. (1999), only one abnormal chart was obtained from the patient and the second evaluation revealed normal visual fields, so it is also possible that the first evaluation had revealed a false positive result and the second evaluation revealed a true negative result or was an artifact or a learning effect. Experience in the evaluation of both unpublished

pediatric series from Finland indicates that as many as 60% of first abnormal visual field results change to normal when the perimetry is repeated (Rintahaka et al., 2000, Vanhatalo, et al. 2001). In addition, recovery in visual fields has been observed after the early detection and withdrawal of the drug in an individual case (Krämer et al., 2000). Some improvement in visual functions has also been reported in single cases after discontinuation of VGB treatment (Lawden et al., 1999, Johnson et al., 2000, Newman et al., 2000, Rintahaka et al., 2000). On the other hand, Wild et al. (1999) have estimated on the basis of cumulative prevalence rates that visual field loss seems not to increase with continuous VGB treatment beyond 4 years.

2.4.3 Contrast and glare sensitivity

The effects of GABAergic agents on visual perception were of interest before the issue of VGB-associated visual field constriction raised concern. In healthy volunteers, a single oral dose of 2-3 g VGB had no effect on spatial contrast sensitivity (Tiel-Wilck et al., 1995, Steinhoff et al., 1997a). In epilepsy patients on CBZ monotherapy, recovery of impaired contrast sensitivity was observed after a combination of VGB as add-on therapy (Sartucci et al., 1997). However, Sartucci et al. (1997) found that contrast sensitivity in epilepsy patients treated with any AED was lower than that in normal controls. In a recent study, Hilton et al. (2001) reported abnormal contrast sensitivity results in 6 out of 11 (54.5%) epilepsy patient treated with current or previous VGB therapy. In pediatric patients with VGB-associated visual dysfunction, loss in contrast sensitivity function has been found with objective evaluation with the sweep VEP (Perron et al., 2001).

Abnormal glare sensitivity has not been observed in epilepsy patients treated with VGB therapy (Bayer, 1991), although in a clinical VGB vs CBZ study, scintillation was reported significantly more in the VGB group than in the CBZ group (Kälviäinen et al., 1995).

2.4.4 Color vision

As retinotoxicity has been suggested to cause VGB-associated visual field defects, it is not surprising that color vision has been examined by several investigators, but earlier studies have also been published concerning VGB's influence on color vision. Single doses of VGB have been reported to not affect color perception in healthy volunteers in two studies (Tiel-Wilck et al., 1995, Steinhoff et al., 1997a), but Mecarelli et al. (2001) found a blue color vision defect in healthy volunteers after a

single dose of 2g VGB. In the thesis by Bayer (1991), five out of eight (63%) patients with VGB add-on therapy had abnormal high total error scores in the FM100 Hue test, and two of them (25%) had a blue axis. Recently, a study was presented where 5 out of 11 (45.5%) epilepsy patient treated with current or previous VGB therapy were found to have abnormal hue perception with the FM100 Hue test (Hilton et al., 2001). Most of the published color vision results have been obtained with only pseudoisochromatic plates, but Panel D-15 arrangement tests have also been used, infrequently. Both normal (Lawden et al., 1999) and abnormal (Johnson et al., 2000, Manuchehri et al., 2000) color perception have been revealed with Ishihara pseudoisochromatic plates in patients with VGB associated visual field defect. Miller et al. (1999) found significantly decreased color perception in 19 out of 32 (59%) VGB patients compared with controls by AO-HRR plates, while Krauss et al. (1998) revealed normal color vision with the same method in 4 patients with VGB-associated visual field defects. More recently, Paul et al. (2001) found abnormal color vision with AO-HRR plates in 5 (23%) of 22 epilepsy patients on VGB add-on therapy, but no deterioration during one-year follow-up. Normal color vision examined with Panel D-15 (Ruether et al., 1998) and with Desaturated Panel D-15 (Besch et al., 2000) has been reported in epilepsy patients with VGB-associated visual field constriction. In addition, normal color vision has been reported in some studies, but without information about the method used (Daneshvar et al., 1999, Newman et al., 2000, Benozzi et al., 2001).

2.4.5 Dark adaptation

In the studies published so far, dark adaptation thresholds have been found to be within normal ranges in patients with VGB-associated visual field defects (Bayer, 1991, Ruether et al., 1998, Besch et al., 2000).

2.4.6 Ophthalmological findings

In most studies and case reports concerning VGB-attributed visual field defects, visual acuities (VA) have been reported as normal (Eke et al., 1997, Krauss et al., 1998, Ruether et al., 1998, Daneshvar et al., 1999, Hardus et al., 2000a, Iannetti et al., 2000, Newman et al., 2000, Russell-Eggitt et al., 2000, Paul et al., 2001). Subnormal VAs have been reported by Miller et al. (1999); the subsequent

follow-up after stopping the drug revealed slight improvement in them (Johnson et al., 2000). Nonspecific retinal abnormalities including retinal arterial narrowing, epiretinal membrane formation, irregular sheen, abnormal pigmentation or RPE abnormalities have been reported (Krauss et al., 1998, Lawden et al., 1999, Miller et al., 1999, Wild et al., 1999). The most frequently reported single ophthalmic sign is optic disc pallor (Eke et al., 1997, Wilson et al., 1997, Wong et al., 1997, Daneshvar et al., 1999, Lawden et al., 1999, Wild et al., 1999, Ponjavic et al., 2000, Buncic et al., 2001, McDonagh et al., 2001).

2.4.7 Electrophysiological changes

2.4.7.1 Visual evoked potentials

A major problem in the clinical development of VGB was intramyelinic edema, which was found in animals after VGB exposure (Gibson et al., 1990). In dogs, these changes were associated with reversible increase in the latency of visual- and somatosensory-evoked potentials (Schroeder et al., 1992). As a result, clinical studies regarding the potential changes in central conduction time in visual pathways were subsequently carried out in epilepsy patients treated with VGB. These evaluations did not reveal any drug-induced detrimental effect on human VEPs (Mervaala et al., 1989, Kälviäinen et al., 1995, Harding et al., 1995 and 2000b, Mauguière et al., 1997, Guberman et al., 2000). In patients with VGB-associated visual field defects, most of the VEP recordings have been normal, suggesting that the primary lesion is unlikely to be within either the visual pathways or visual cortex (Eke et al., 1997, Krauss et al., 1998, Ruether et al., 1998, Lawden et al., 1999, Wild et al., 1999, Harding et al., 2000b, McDonagh et al., 2001). However, reduced amplitudes and increased latencies have been found in individual patients (Krauss et al., 1998, Daneshvar et al., 1999, Miller et al., 1999). In a study evaluating pediatric patients receiving VGB, five out of eleven (45%) epilepsy patients who underwent VEP examination had prolonged latencies; all these patients had visual field defects (Gross-Tsur et al., 2000). In a study by Zgorzalewicz et al., (2000) of pediatric patients treated with VGB as add-on treatment, VEP abnormalities were observed in 10-20% of young epilepsy patients with CBZ or VPA monotherapy, and add-on therapy with VGB did not increase the percentage of pathological results. However, it has to be remembered that conventional pattern VEP only evaluates the central 10° of the visual field and may miss more peripheral dysfunction.

2.4.7.2 Electroretinogram

Electroretinograms have been shown to be affected by the GABAergic system in animals (Massey et al., 1982, Kупenova et al., 1991, Arnarsson and Eysteinnsson, 1997, Horiguchi et al., 1998, Plazonnet et al., 2001). The effect of VGB on ERG has also been shown in healthy volunteers; administration of a 1 to 2 g daily dose of VGB in a 10-day period increased significantly the latency of photopic b-wave in such groups compared with CBZ and placebo groups, but no changes in oscillatory potentials were observed (Harding et al., 1999). After the drug was stopped, the measurements became normal again. Thus, the retinal electrophysiology associated with VGB has been found to be complex. Harding et al. (2000a) suggested that the changes in the ERG may be unrelated to the presence of visual field loss, and improved after withdrawal of the drug. Also in another study, the photopic b-wave has been shown to be affected by current VGB therapy rather than by the visual field loss, and to represent normal physiologic effects of elevated retinal GABA (Duckett et al., 1998). In pediatric epilepsy patients, Westall et al. (2000) found significant reduction in oscillatory potentials after six months VGB therapy in patients without VGB during initial examinations, whereas patients on VGB at the time of the initial visit showed no progression in ERG responses between the first and follow-up visits. A six-week period of VGB add-on treatment caused a delay in b-wave, reduction in b-wave amplitude and marked reduction in oscillatory potentials as compared with pretreatment results in 36 of 140 pediatric patients with refractory epilepsy (Duckett et al., 1998). In the follow-up, progression of the ERG abnormalities was seen in 78 out of 171 (46%) patients (Brigell et al., 2000). The authors suggested that there are two effects of VGB on the ERG: an early physiologic effect of elevated retinal GABA, and a progressive effect on the outer retina, which implies a risk of associated visual field defect.

Abnormalities in ERGs have been identified since the publication of the earliest reports of VGB-attributed visual field defects. Typical changes are increases in photopic b-wave latencies, reduction of the b-wave amplitude, and markedly reduced or absent oscillatory potentials, suggesting inner retinal damage involving Müller cells (Bayer, 1991, Eke et al., 1997, Krauss et al., 1998, Ruether et al., 1998, Arndt et al., 1999a, Daneshvar et al., 1999, Miller et al., 1999, Wild et al., 1999, Gross-Tsur et al., 2000, Coupland et al., 2001, Hardus et al., 2001b, McDonagh et al., 2001). In several studies (Miller et al., 1999, Harding et al., 2000a,b, Coupland et al., 2001, Ponjavic and Andréasson, 2001), the most consistently occurring electrophysiologic variance with VGB associated visual field defects was the 30-Hz flicker cone wave amplitude. Harding et al. (2000a,b) concluded that the measurement of the amplitude of the cone flicker response is sufficiently sensitive

(100%) and specific (75%) for VGB associated visual field defects that it can be used to screen patients in whom perimetry cannot be reliably performed. On the other hand, Hardus et al. (2001b) showed that electrophysiology does not appear to be a good method to detect patients with, or at risk of, VGB-associated visual field loss. In multifocal ERGs, marked reduction in peripheral parts of the stimulated area has been observed (Lawden et al., 1999, Harding et al., 2000b, Johnson et al., 2000, Ponjavic and Andréasson, 2001, McDonagh et al., 2001).

A correlation has been found between the ERG changes and the duration of VGB therapy (Gross-Tsur et al., 2000, Herbert et al., 2000, Coupland et al., 2001, Hardus et al., 2001b), and between the ERG abnormalities and the severity of the visual field defects (Miller et al., 1999, Harding, 2000a, Hardus et al., 2001b). Mild reversal of ERG changes after discontinuation of VGB has been reported in individual patients by Johnson et al. (2000) and Krakow et al. (2000).

2.4.7.3 Electro-oculogram

Reduction of the Arden Index in the EOGs has been found in the evaluation of patients with VGB attributed visual field defects (Eke et al., 1997, Krämer et al., 1997, Arndt et al., 1999a, Daneshvar et al., 1999, Laplace et al., 2000, Coupland et al., 2001), but normal EOGs have been reported as well (Harding et al., 2000b, McDonagh et al., 2001). Epilepsy patients with current VGB therapy but without visual field defects have shown altered Arden Index or EOG amplitudes, possibly indicating more the efficacy than the toxicity of the drug (Rebolleda et al., 2000, Laplace et al., 2000, Harding et al., 2000a). It has also been noticed that the Arden Index was significantly reduced in patients who were taking VGB at the time of EOG examination, while patients who had previously been exposed to VGB, but had discontinued the drug before EOG examination, showed nearly normal results (Lawden et al., 1999, Coupland et al., 2001).

2.5 The influence of tiagabine on the visual system

2.5.1 Retina

In isolated animal retinas, a GABA uptake blocker, nipecotic acid, the analog of which is TGB, has been found to affect photopic ERG and intracellular potentials of horizontal cells (Massey et al., 1982, Perlman and Norman, 1990, Arnarsson and Eysteinnsson, 1997). Recently, Sills et al. (2001)

have found that TGB, in doses of 5, 10 or 20 mg/kg, has no effect on GABA concentrations or on the activity of GABA-T in the rat retina. Unlike VGB, TGB has not been found to accumulate in the rat retina (Sills et al., 2001).

2.5.2 Visual fields

Visual symptoms such as dose-related transient nystagmus and blurring of vision but no visual field defects have been reported in clinical TGB trials (Leppik et al., 1999, Fakhoury et al., 2000a). In an evaluation by Collins et al. (1998), incidence data from all phase II and phase III clinical TGB trials were examined for adverse events potentially relating to visual field defects. Eight patients (0.3%) out of 2531 had complaints which might be ascribed to visual field changes; two patients had localized visual field defects from earlier brain lesions and six had transient visual disturbances. Three of the six symptoms resolved without intervention, and three others after reduction of TGB or concomitant AED dosage. The shortcoming of this evaluation is that the visual field testing was performed only with confrontation.

As an other GABAergic AED, progabide, was reported to affect visual fields in a similar manner to that of VGB (Baulac et al., 1998), TGB as well as other AEDs with GABAergic mechanisms of action became questionable (Rao et al., 1998, Beran et al., 1998, 1999). Only two reports have presented visual field defects associated with TGB treatment. Beran et al. (1998, 1999) reported that 6 patients out of 12 on TGB had asymptomatic visual field constriction. Their results have been published only in abstract form and the clinical details of the patients, for instance the possible earlier use of VGB, have not been reported. Kaufman et al. (2000) have published one case report about a reversible visual field loss associated with TGB treatment. They presented a psychiatric patient who was examined with repeated automated perimetries after 12 and 18 months exposure to TGB, and after discontinuation of the drug. In the Full Field 120-point test, there were initially 7/120 (right eye) and 1/120 (left eye) absolute defects, increasing during the follow-up to 9/120 and 6/120. After the drug had been stopped, the number of missing points gradually decreased to 7/120 and 3/120.

A few evaluations presenting negative results have been published regarding TGB and visual field defects. Kinetic Goldmann and automated Humphrey perimetries did not reveal visual field constrictions in 8 epilepsy patients treated with TGB (Fakhoury et al., 2000b). Preliminary results of a multicenter study on epilepsy patients receiving TGB monotherapy and matched controls receiving CBZ or lamotrigine monotherapy have been published as a congress abstract (Kälviäinen et al.,

2000). In that paper, no concentric visual field defects were found in 28 patients treated with initial TGB monotherapy. The mean daily dose was 15.9 mg (range 10-20 mg) and the mean treatment duration 26.3 months (range 3-58 months). Both Goldmann and Humphrey perimetries were used in this study.

2.5.3 Visual function tests

The above-mentioned evaluations and case reports regarding visual functions in epilepsy patients treated with TGB did not present records relating to color vision, contrast or glare sensitivity, dark adaptation or electrophysiology.

2.6 The influence of carbamazepine on the visual system

Carbamazepine may cause ophthalmic adverse effects which are considered to originate at the level of the brainstem and cerebellum (Mattson, 1998). The ocular adverse effects of CBZ involve mainly the extraocular muscles, causing diplopia and nystagmus as a symptom (Zaccara et al., 1992), but accommodative problems can occur as well. Because of these various neurotoxic effects of CBZ, many investigators have become interested in the effects of CBZ on visual functions.

2.6.1 Retina

The possible retinotoxic effect of CBZ has been suggested by Vesti Nielsen and Syversen (1986). They presented two patients with epilepsy and with more than seven years of CBZ therapy who developed decreased visual acuity and paracentral scotoma. Both had retinal pigment epithelial changes in the ophthalmoscopy and fluorescein angiography. The changes were reversible after cessation of CBZ. As CBZ is widely used in the treatment of epilepsy as well as in other neurological conditions, it is obvious that the retinotoxic effect of CBZ is rather uncommon.

2.6.2 Visual fields

Slight concentric constriction of visual fields has been reported in epilepsy patients treated with CBZ (Zrenner and Nowicki, 1985), and patients with possible CBZ-associated retinopathy had either normal visual fields or paracentral scotoma (Vesti Nielsen and Syversen, 1986). In the thesis by Bayer (1991), patients with CBZ monotherapy were found to have normal visual fields with automated Octopus perimetry. Only one patient with combination therapy with CBZ, DPH and phenobarbital had concentric visual field loss: the author suggested that the cause was DPH.

2.6.3 Contrast and glare sensitivity

Epilepsy patients with long-term CBZ monotherapy showed impaired contrast sensitivity in all examined spatial frequencies (0.5 to about 20 cpd) in two controlled studies (Tomson et al., 1988, Sartucci et al., 1997), while Paulus et al. (1996) and Steinhoff et al. (1997b) found no alterations in perception thresholds for sinusoidal gratings in epilepsy patients receiving CBZ monotherapy. A single oral dose of 400 mg CBZ has been found not to change spatial contrast sensitivity in healthy volunteers (Tiel-Wilck et al., 1995, Steinhoff et al., 1997a).

Bayer (1991) and Bayer et al. (1991a,b and 1995a,b) have investigated mesopic vision in epilepsy patients using a Rodenstock-Nyktometer with and without glare. They found that mesopic vision and especially glare sensitivity in dim circumstances were markedly affected in epilepsy patients treated with CBZ monotherapy compared with normal controls.

2.6.4 Color vision

A single oral dose of 400 mg CBZ in healthy volunteers has been found not to affect color vision measured with the desaturated Lanthony 15 test (Steinhoff et al., 1997a), whereas non-standardized color VEP and color perimetry tests revealed mild impairment in both red and blue chromatic systems (Mecarelli et al., 2001). In epilepsy patients with long-term CBZ monotherapy, acquired color vision defects, i.e. high total error scores and blue axes, have been found with the FM100 Hue test (Zrenner and Nowicki, 1985, Bayer, 1991, Bayer et al., 1991b, Bayer et al., 1995 a,b, Paulus et al., 1996, 1997). However, Steinhoff et al. (1997b) found no significant color vision defects with the Desaturated Lanthony 15 test in CBZ monotherapy patients. Recently, the FM100 Hue test revealed

significant abnormalities in color perception, mainly in the blue-axis, in 8 out of 12 (67%) patients on CBZ monotherapy (López et al., 1999). In a study by Bayer et al. (1997), newly diagnosed epilepsy patients who were treated with initial CBZ monotherapy developed blue-yellow color vision defects in the FM100 Hue test during a follow-up period of 18 months. These defects were also found with the Tritan Screening Plates. On the other hand, the patients with possible CBZ-induced retinopathy had normal color vision with the Ishihara and AO-HRR tests (Vesti Nielsen and Syversen, 1986).

2.6.5 Dark adaptation

Only a few reports, all of which reported normal dark adaptation curves, have been published concerning dark adaptation during CBZ therapy (Zrenner and Nowicki, 1985, Vesti Nielsen and Syversen, 1986, Bayer, 1991, Bayer et al., 1995a).

2.6.6 Electrophysiological changes

Significantly prolonged VEP latencies reflecting slowing in impulse conduction have been reported in epilepsy patients receiving CBZ monotherapy as compared with patients on VGB monotherapy (Mervaala et al., 1989, Kälviäinen, 1992, Kälviäinen et al., 1995). In his thesis, however, Bayer (1991) found normal VEP latencies in all patients on CBZ who underwent VEP examination. Harding et al. (1999) examined the effects of an increasing dose of 400 to 800 mg CBZ over a period of 10 days on ERG and EOG in healthy volunteers. Neither ERG nor EOG changed significantly when measured at the baseline and on days two, four and nine.

3 AIMS OF THE STUDY

In 1997, three cases of severe symptomatic and persistent visual field constriction associated with VGB treatment were described (Eke et al., 1997). During the period 1997 to 1998, similar concentric visual field constrictions were reported in symptomatic and asymptomatic patients with drug-resistant epilepsy. Most patients had refractory epilepsy and also used other AEDs as polytherapy, and a causal relationship between visual field defects and VGB treatment was not established. The electrophysiological changes reported in these patients suggested retinal damage as a mechanism of the visual field defects (Krauss et al., 1998).

The aim of the present series of studies (I-V) was to answer the following questions:

1. Is there a causal link between AED therapy with VGB and concentric visual field defects? (I)
 - a) What is the prevalence of VGB-associated visual field defects? (I, II)
 - b) Are VGB-associated visual field defects reversible after discontinuation of the drug, or progressive with continued therapy? (II)
 - c) Are there risk factors for VGB-associated visual field defects? (I, II)
 - d) Are VGB-related visual field defects associated with impairment in visual function, such as contrast and glare sensitivity or color vision? (III, IV)
2. Are concentric visual field defects a class effect of GABAergic antiepileptic drugs? (V)
3. What is the influence of AED monotherapy with TGB or CBZ on visual function? (III, IV, V)

4 PATIENTS AND METHODS

4.1 Study design

The present study consists of five original publications, four of which are cross-sectional comparative clinical trials (I,III-V) and one of which is a follow-up study (II). Clinical examinations were carried out at the Departments of Ophthalmology, Neurology, Neuroradiology and Clinical Neurophysiology in Kuopio University Hospital and at the Department of Ophthalmology in Turku University Hospital during 1997-2000. All ophthalmological examinations were carried out by the author, excluding the automated perimetry in study V and the neuro-ophthalmological examination on 8 patients in Turku University Hospital in study I.

4.2 Patients

During the years 1988-95, 135 patients with newly diagnosed partial epilepsy had been randomly assigned to either VGB or CBZ monotherapy groups in the Department of Neurology in Kuopio University Hospital for a comparative VGB vs. CBZ monotherapy study (Kälviäinen, 1992, Kälviäinen et al., 1995). For the present cross-sectional studies (I, III, IV) and for a part of the follow-up study (II) we identified 32 patients on VGB and 18 patients on CBZ still successfully using their study treatment as monotherapy and attending the outpatient Department of Neurology in Kuopio University Hospital. The two groups were found to be comparable in terms of demographic data. Three additional VGB monotherapy patients were identified for the follow-up study (II).

Most of the VGB monotherapy patients, i.e. 29 out of 35 had VGB as their initial treatment, but six patients who had switched to VGB monotherapy after failure with conventional AED monotherapy were also investigated. The patient population in the follow-up study (II) consisted of all cooperative patients in the outpatient department of neurology who had used VGB as monotherapy or as add-on treatment for at least 6 months irrespective of their individual decision whether to continue the treatment or not. All patients treated with VGB received oral and written information about VGB-related visual field defects at the time when the risk was discovered. Participation in the study did not influence their treatment choice. In clinical practice we followed up some of the VGB patients (especially those who continued with VGB) every six to twelve months.

The TGB monotherapy group comprised a subgroup of 40 epilepsy patients, who had converted to TGB monotherapy during the years 1995-1997. They had had either unsatisfactory

seizure control and/or unacceptable adverse effects with their earlier AED monotherapy. Fifteen patients out of 16 still continuing with TGB monotherapy were examined. One patient was excluded due to bilateral cataracts. One patient treated with TGB monotherapy had optic nerve atrophy and homonymous hemianopsia; he was excluded from statistical analyses and from contrast sensitivity and color vision studies.

Seventeen of the 18 CBZ monotherapy patients had CBZ as their initial treatment but one patient did not respond to VGB monotherapy during the titration phase and was switched to CBZ as her second monotherapy. The plasma concentration of CBZ was within the reference range (20-50 $\mu\text{mol/l}$) in all patients.

All patients were outpatients who suffered from partial epilepsy with or without secondary generalization. The patients with VGB, TGB and CBZ monotherapy and 11 of the patients with VGB add-on therapy were seizure-free or satisfactorily controlled with therapy. In the add-on group, there were 14 patients who had refractory epilepsy with continuous seizures despite drug therapy. Normal general intelligence had been confirmed with formal neuropsychological tests in VGB, TGB and CBZ monotherapy patients (Kälviäinen et al., 1995, Kälviäinen et al., 1999).

Table 4. Number of patients and controls in studies I-V.

	Study I	Study II	Study III	Study IV	Study V
VGB monotherapy	32	35	32	32	
VGB add-on therapy		25			
TGB monotherapy					15
CBZ monotherapy	18		18	18	
Controls	18	18	47	35	18 VF, 35 CS

VF visual fields, CS contrast sensitivity

Table 5. Demographics and characteristics of the epilepsy patients in studies I-V (mean \pm SD).

	VGB monotherapy	VGB add-on therapy	TGB monotherapy	CBZ monotherapy
Number of patients	35	25	15	18
Age (years)	41 \pm 16	40 \pm 13	52 \pm 12	44 \pm 18
Range	20 - 74	17 - 62	31 - 71	20 - 70
Female, n	21	14	9	12
Male, n	14	11	6	6
Daily dose	2.7 \pm 0.6 g	2.6 \pm 0.6 g	21 \pm 13 mg	719 \pm 172 mg
Range	2 - 4 g	1 - 5 g	5 - 60 mg	400 - 1000 mg
Cumulative dose	6 \pm 3.6 kg	3.8 \pm 4.0 kg	25 \pm 17 g	
Range	1.8 - 18.7 kg	0.42 - 18.0 kg	4.5 - 68 g	
Duration of the therapy (months)	70 \pm 30	49 \pm 36	38 \pm 10	61 \pm 26
Range	29 - 120	7 - 168	23 - 55	32 - 108
Etiology of epilepsy				
Cryptogenic, n	23	13	8	15
Symptomatic, n	12	12	7	3

4.3 Controls

Over several years, we have investigated under standardized conditions normal values of visual function tests for different age groups in the Department of Ophthalmology in Kuopio University Hospital. Of these source data, we selected results of all age- and gender-matched normals for the statistical analyses of FM100 total error scores (Mäntyjärvi, 2001) and contrast sensitivity results in the studies III-V (Mäntyjärvi and Laitinen, 2001). The normal controls for Goldmann perimetry were examined especially for this study. The healthy volunteers comprised staff and outpatients in the Department of Ophthalmology in Kuopio University Hospital and, students in the University of Kuopio. All controls were interviewed in order to exclude those with ophthalmological disorders.

4.4 Approval of the Ethics Committee

The study was approved by the Ethics Committee of Kuopio University Hospital and the University of Kuopio. Informed written consent was obtained from the patients.

4.5 Ophthalmological examination (I-V)

The clinical examination included determination of the best corrected VA, measurement of the intraocular pressure with the Goldmann applanation tonometry, assessment of ocular motility, alignment and pupillary reactions, biomicroscopy of the anterior segment, and fundus examination using non-contact fundus lenses (Volk 90 or Volk Superfield), and a three-mirror contact lens when needed.

Best corrected VA was measured at 5 meters with a Nikon chart projector. The results were also converted to LogMAR acuities (Ferris et al. 1982). Refraction was determined using retinoscopy with both normal-sized and dilated pupils. The presence of phorias and tropias was assessed at distance (5m) and at near (30cm), and motility, convergence and pupillary reactions were observed. Dilatation of the pupils was induced with tropicamide 0.8% + phenylephrine 5% drops.

4.6 Visual fields

4.6.1 Kinetic perimetry (I, II, V)

Visual fields were examined in a dark room, the right eye first followed by the left eye, with the standard manually operated kinetic Goldmann perimeter (Haag-Streit, Bern, Switzerland). White test stimuli, Goldmann size of IV (16mm^2) and I (0.25mm^3) with a background luminance of 31.5 apostilbs ($10\text{ candela}/\text{m}^2$) were used. The light intensity of the target was 4 (1000 apostilb) in examining the peripheral isopter with stimulus IV, and 3 (315 apostilb) in examining the central isopter and the blind spot with stimulus I. Before the examination, the calibration of the perimeter was done according to the instructions of the manufacturer. Patients had normal-sized pupils and intraocular pressure was measured after the visual field examination. Peripheral field was examined without corrective lenses but age-dependent near vision correction was added to the distance correction in patients over 40 year old when the central part of the visual field was examined.

Prior to the examination, patients adapted to the background illumination for 2 to 3 minutes. During the examination, the stimulus was moved from the periphery to the centre of the visual field with a speed of about 2-5° per second. All meridians spaced every 15° were examined. The fixation was observed during the examination through a checking device. The writer performed all kinetic visual field examinations, masked for the treatment group in study I. To confirm the results, eight patients from the VGB monotherapy group (2 with severe constrictions, 5 with mild constrictions and

1 with normal visual fields) were checked by an experienced neuro-ophthalmologist, professor Eeva Nikoskelainen in Turku University Hospital without knowledge of previous visual field findings.

The results of the Goldmann perimetry were estimated using an empirical semi-quantitative procedure: a visual field (isopter IV/4) extending over 70° temporally was considered as normal (Galan, 1968, Egge, 1984), from 50° to 70° as mildly abnormal, and a visual field narrower than 50° temporally as severely abnormal (Figure 3). The largest isopter (IV/4) was measured in degrees in the cardinal meridians (i.e. temporal, nasal, superior and inferior) for the statistical evaluation.

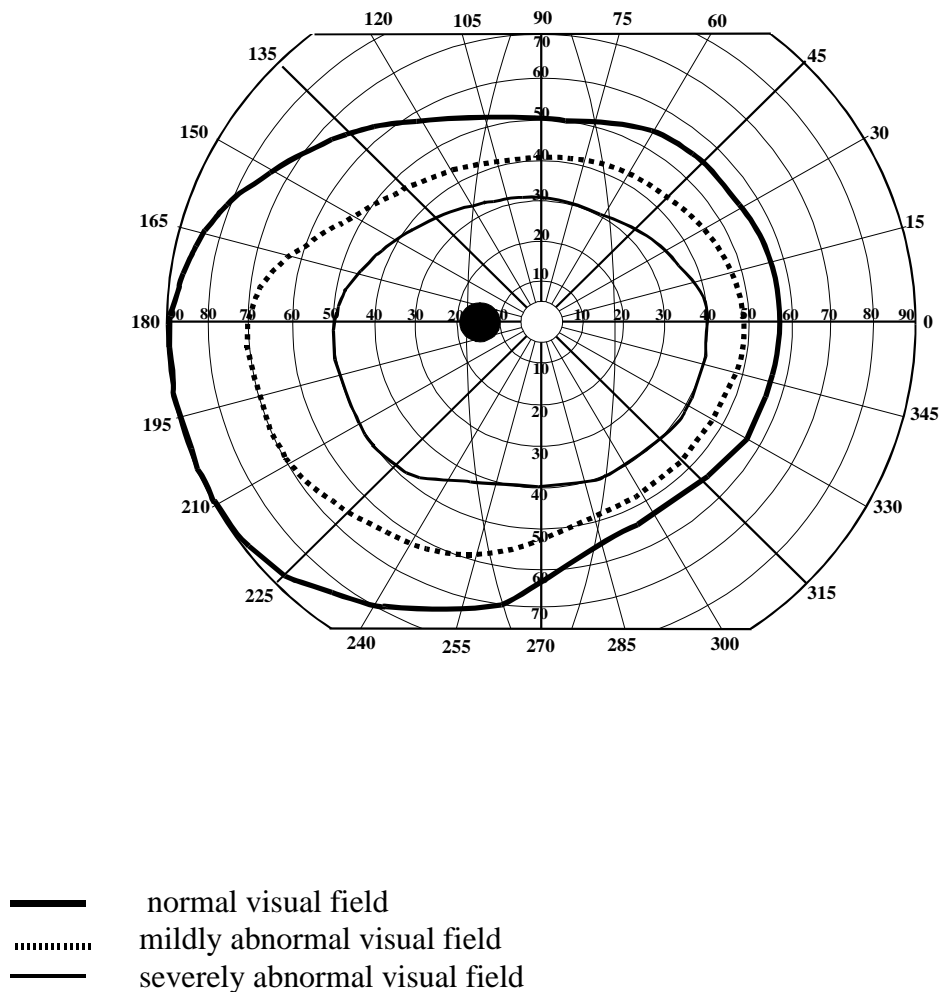


Figure 3. The extents of the normal visual field (left eye) and the limits of mild and severe defects used in this study.

4.6.2 Static perimetry (V)

Automated static perimetry was performed with a Humphrey Field Analyser Mark 2 (HFA, Humphrey systems, Dublin, CA) using the standard age-corrected Full Field 120 two-zone suprathreshold strategy. The visual field out to 60° from the central fixation was examined. Near vision correction was calculated using Humphrey's internal algorithm and used when central visual field was examined. Static visual field examinations were performed with normal-sized pupils and the right eye was examined first, followed by the left eye. Static suprathreshold perimetry was considered abnormal if three or more adjoining points were missed.

4.7 Contrast sensitivity (III, V)

Contrast sensitivity was measured monocularly with the Pelli-Robson letter chart (Clement Clarke International Ltd. Harlow, Essex, U.K.; Pelli et al., 1988, Rubin, 1988) under conditions of constant illumination of 100 cd/m² (accepted range for the Pelli-Robson test from 60 to 120 cd/m²). The test distance was 3 m, corresponding to the spatial frequency of 3 cpd. The patient's own distance correction or the best correction on trial frames were used. The logarithmic contrast sensitivity value of the last triplet of which at least two letters were correctly seen was marked as the result. Normal values published by Mäntyjärvi and Laitinen (2001) were used in assessing individual results.

4.8 Glare sensitivity (III)

Brightness acuity and macular photostress tests were performed monocularly with the Mentor BAT (Marco Ophthalmic Inc., Jacksonville, Fla) in 32 VGB monotherapy patients and in 18 CBZ monotherapy patients. With the device, it is possible to produce a full hemispherical light source at a distance of 64 mm from the eye. In the BAT, the best corrected distant VA was measured without glare and with low, intermediate and high glare (41, 342 and 1370 cd/m²) using the same high-contrast projector in a dark room as in the normal VA testing. In the results, the worsening of two lines in VA was accepted as normal. In the macular photo-stress test, consistent high glare (1370 cd/m²) was maintained for 15 s, and the length of time required for the VA to recover to two lines above the line of the best corrected VA was recorded. The normal recovery time of 0 to 30 seconds was used in assessing the individual results (Glaser et al., 1977). Both glare sensitivity examinations

were made with normal-sized pupils without dilatation and with patients' own distance correction or with the best correction on trial frames.

4.9 Color vision (IV, V)

The color vision examination consisted of a battery of pseudoisochromatic plates, a hue discrimination test, and metameric matches. The right and left eye were examined separately in a random order, and near vision correction was used in all color vision tests when needed. The illumination for SPP2 and FM100 Hue tests was provided by a Macbeth Easel lamp (Newburgh, NY, U.S.), 1000 lux. Cases where ophthalmic disorders might have interfered with color vision were excluded.

4.9.1 Standard Pseudoisochromatic Plates 2

Standard Pseudoisochromatic Plates part 2 (SPP2, Ichikawa et al., 1983) are designed to detect both acquired and congenital color vision defects (Tanabe et al., 1984, Ichikawa et al., 1987). The test consists of 12 pseudoisochromatic plates, two of which are demonstration plates and the other 10 are diagnostic plates with 5 red-green and 10 blue numbers. The testee passes the test if at least 5/5 red-green numbers and 9/10 blue numbers are named correctly (Tanabe et al., 1984).

4.9.2 Farnsworth-Munsell 100 Hue test

The color discrimination ability was examined with the FM100 Hue test. The error scores were calculated according to Kinnear (1970), as square roots, and the age-dependent normal values of Verriest et al. (1982) were used in assessing individual results. The normal values of Smith et al. (1985) were used in assessing individual axes. Calculations were performed and diagrams were drawn using FM Scoring Software Version 2.1 (Macbeth Division of Kollmorgen Corp., 1997). Because the FM100 total error score is highly dependent on the age of the subject, the age was added as a covariate in the statistical comparison of the FM100 results. Due to fatigue, one patient in the VGB monotherapy group and one patient in the TGB monotherapy group performed the FM100 Hue test only with one eye.

4.9.3 Color Vision Meter 712 anomaloscope

Metameric matches were investigated with a computer controlled electronic Color Vision Meter 712 anomaloscope (CVM 712, Interzeag, Schlieren, Switzerland) where red, green (Rayleigh equation) and blue (Moreland equation) color vision was examined. The stimulus was presented for 2 seconds on a bipartite field of 2 σ , with an achromatic field between the presentations to maintain the adaptation level. The matching ranges (MR) and mid matching points (MMP) for both equations were recorded, and the anomalous quotients (AQ) were calculated according to Birch et al. (1979). In calculations we used the normal values examined earlier with the same instrument in our clinic (Maaranen et al., 2000). Values from 0.7 to 1.3 in the Rayleigh equation and from 0.7 to 1.4 in the Moreland equation were considered normal AQs, and values from 0 to 10 in the Rayleigh equation and from 0 to 11 in the Moreland equation normal MRs.

4.10 Dark adaptation (III)

The dark-adaptation examination was done monocularly in the right eye with the Goldmann-Weekers Adaptometer (Haag-Streit, Bern, Switzerland) according to the instructions for the absolute threshold, and only the rod threshold was examined in both eyes. After a short adaptation in complete darkness, the light-adaptation of cones was done in 5 minutes in the brightly illuminated sphere before the dark-adaptation examination. The dark adaptation curve obtained is biphasic, with an early rapid increase in cone sensitivity and a delayed slower increase in rod sensitivity. Values from 3.8 to 4.6 log units (mean 4.2 ± 0.2) for the cone threshold and from 5 to 9 min (mean 7 ± 1) for time, and from 1.8 to 2.4 log units (mean 2.13 ± 0.15) for the final rod threshold and from 22 to 32 min (mean 27 ± 2.5) for time, were accepted as normal. These normal values were calculated in 51 normal volunteers aged from 10 to 69 years at our clinic.

4.11 Electroretinogram (I)

Electroretinogram was performed on patients who had abnormal visual fields, to further evaluate the pathogenesis of the defects. ERG was performed with a Nicolet Ganzfield stimulator according to the recommended standards of the International Society for the Clinical Electrophysiology of Vision (ISCEV) (Marmor et al., 1989, Celesia et al., 1993). Tropicamide 0.5% drops were used for dilating

the pupils, and corneal contact lens electrodes were positioned after applying oxibuprocaine drops for topical anesthesia. In accordance with the ISCEV standards, after the dark adaptation for at least 20 minutes, the rod response, maximal combined response, oscillatory potentials and cone response were recorded.

4.12 Neuroradiology (I)

At the time of epilepsy diagnosis, CT or MRI examinations were performed to determine the etiology of epilepsy in each patient. During study I, MRI was repeated in those VGB monotherapy patients who had abnormal visual fields. The examinations were performed with a 1.5 T Magnetom Vision (Siemens, Erlangen, Germany), special attention being paid to orbit, visual pathways, and occipital lobes.

4.13 Statistical methods (I-V)

Statistical analysis was performed with the SPSS/PC Version 9.1 and 10.0 (Chicago, Ill.) and Statview 512 + (Berkeley, CA) programs. The results of continuous variables are presented as means \pm standard deviations (SD). The chi-square test was used to compare frequencies in different groups and the two-tailed T-test to compare continuous parameters between two groups. The non-parametric Mann-Whitney and Kruskal-Wallis tests were used when the number of observations was less than ten. One-way analysis of variance (ANOVA) for independent observations with Scheffe's and LSD posthoc tests was used to compare more than two groups. The significance of the change between two different measurements of the same parameter was tested with the paired T-test. Linear regression was used to assess the correlation between parameters and clinical variables. The confidence interval (CI) of 95% was calculated from important prevalences. P values of <0.01 (studies I and V) and <0.05 (studies II, III, IV) were considered significant. In individual assessment of the results, the mean of the normals $\pm 2SD$ was considered the limit of normality.

5 RESULTS

5.1 History and visual symptoms (I-V)

The presence of visual symptoms and the history of previous ophthalmic diseases was elicited at the beginning of the examination. None of the patients (I-V) or normal controls complained about current visual problems before the examination, and none had diagnosis or suspicion of glaucoma or ocular hypertension in the history.

A 54-year-old male in the VGB monotherapy group had had a perforating injury in his right eye in 1968. He had traumatic aphakia, and corneal and retinal scars. A 32-year-old female in the VGB monotherapy group had congenital microphthalmos with pupil and lens abnormalities in her right eye.

In study V, one patient had previously been documented as having bilateral optic nerve atrophy and homonymous hemianopia: the etiology of visual field defects was occipital infarct probably caused by birth trauma. A 58-year-old man had undergone 4 years earlier bilateral focal photocoagulation for peripheral retinal degeneration (20 burns per eye with energy of 180 mW, spot size of 200 μm and exposure time of 0.1 sec). Four patients had undergone intra-cranial operations for benign tumors or vascular abnormalities but they did not complain of any problems in seeing.

After the examination, the VGB patients with abnormal fields were again asked about symptoms, but only two reported any; complaining about repeatedly bumping into people or furniture, or stumbling over a cat. All other patients who had visual field defects were asymptomatic.

5.2. Ophthalmological findings (I-V)

5.2.1 Visual acuity

The VAs of patients are presented in Table 6. In the VGB monotherapy group, the patient with aphakia had corrected VA 0.6 (LogMAR +0.2) in the affected eye, and the patient with microphthalmos counted fingers with the affected eye. In the VGB add-on therapy group, one patient with strabismic amblyopia had corrected VA 0.2 (LogMAR +0.4) in the affected eye. The VAs in the patients treated with VGB did not change during the follow-up time. One way ANOVA with Scheffe's post hoc test did not reveal significant differences in visual acuities between the groups.

Table 6. Visual acuities in patients treated with VGB, TGB or CBZ monotherapy or with VGB add-on therapy (mean \pm SD).

	Snellen (RE)	Snellen (LE)	LogMAR (RE)	LogMAR (LE)
VGB monotherapy (n = 33 RE, 35 LE)	0.96 \pm 0.078	0.97 \pm 0.087	0.018 \pm 0.039	0.017 \pm 0.045
Range	(0.8 - 1.0)	(0.7 - 1.0)	(0- + 0.1)	(0- + 0.1)
VGB add-on therapy (n = 25)	0.99 \pm 0.177	1.02 \pm 0.074	0.019 \pm 0.141	-0.008 \pm 0.027
Range	(0.2 - 1.33)	(1.0 - 1.33)	(-0.1 - + 0.7)	(-0.1 - 0)
CBZ monotherapy (n = 18)	0.96 \pm 0.078	0.94 \pm 0.086	0.033 \pm 0.049	0.033 \pm 0.049
Range	(0.8 - 1.0)	(0.8 - 1.0)	(0- + 0.1)	(0- + 0.1)
TGB monotherapy (n = 15)	0.97 \pm 0.168	0.97 \pm 0.183	0.027 \pm 0.110	0.020 \pm 0.115
Range	(0.4 - 1.2)	(0.4 - 1.2)	(-0.1 - +0.4)	(-0.1 - +0.4)

RE right eye, LE left eye

5.2.2 Alignment, motility and pupillary reactions

The patients with aphakia and amblyopia had manifest divergent squint, and some patients had non-significant phorias. One patient on VGB monotherapy and one on CBZ monotherapy had undergone earlier strabismic surgery, but neither of them currently had manifest squint. All patients had normal pupillary reactions to light and convergence with the exception of restricted reactions in the aphakic and microphthalmic eye.

5.2.3 Biomicroscopy

The two patients described above in the VGB monotherapy group showed changes in the anterior structures of the eye on biomicroscopy. In the TGB group, one patient had slight nuclear sclerosis: all others had clear lenses.

5.2.4 Intraocular pressure

Intraocular pressure was within normal ranges ≤ 21 mmHg in all patients.

5.2.5 Ophthalmoscopy

Slight pallor of the optic discs was found in 7 patients with VGB treatment: in 3 VGB monotherapy patients and in 4 add-on patients. All these patients had severely constricted visual fields. Previously documented optic nerve atrophy was found in one TGB monotherapy patient. None had glaucomatous optic nerve cupping. The patient with a previous perforating injury had retinal scars in the affected eye. Minor changes in the RPE (scars or defects near the macular area) were found in two patients; one with VGB monotherapy, and one with TGB monotherapy. In addition, one patient in TGB monotherapy group had minor laser-scars in the superior periphery of both eyes.

5.3 Visual fields

5.3.1 Kinetic perimetry (I, II, V)

In the clinical evaluation of the kinetic visual fields of monotherapy patients (Study I), 13 of 32 patients (40%, 95% CI 23%-57%) treated with initial VGB monotherapy had concentric visual field constriction, whereas all patients treated with CBZ monotherapy and healthy controls had normal visual fields. The defect was severe in 3 patients (9%, upper 95% CI 19%) and mild in 10 patients (31%, 95% CI 15%-47%) treated with VGB monotherapy.

In the whole group of patients on VGB (study II), clinical evaluation revealed concentric constriction of the visual fields in 24 of 60 patients (40%, 95% CI 28%-52%). Severe constriction of the visual fields was found in 8 patients with previous or present VGB medication (13%, 95% CI 9%-17%). Four of these had received VGB as monotherapy and four as add-on therapy. Mild constriction was found in 16 patients (27%, 95% CI 21%-33%), 10 in the monotherapy group and 6 in the add-on group (Table 7).

Three patients treated with TGB monotherapy had localized defects, one homonymous hemianopia and two quadrantanopias from earlier documented brain lesions. None in the TGB monotherapy group had concentric visual field constriction.

Table 7. Clinical evaluation of the visual fields in patients treated with VGB monotherapy or add-on therapy (number of patients (%) with 95% CI).

	Monotherapy n = 35	Add-on therapy n = 25	Total n = 60
Visual fields			
Normal, n	21 (60%)	15 (60%)	36 (60%)
Mildly abnormal, n	10 (29%)	6 (24%)	16 (27%) (95% CI 21%-33%)
Severely abnormal, n	4 (11%)	4 (16%)	8 (13%) (95% CI 9%-17%)

A significant difference was found between the groups in all cardinal meridians of the visual field extents (one-way ANOVA; $p < 0.0001$ in all meridians). The differences between the groups revealed by Scheffe's posthoc test are presented in Table 8. Both the VGB monotherapy and add-on therapy groups showed a significant difference when compared with controls in all meridians of both eyes. There was no significant difference between the right and left eye in visual field extents in any group. Patients with localized visual field defects in the TGB group and one patient in the VGB add-on group, due to unreliable performance in visual field examination, excluded from the statistical analysis.

Table 8. Visual field extents in degrees in the cardinal meridians (mean \pm SD).

	VGB monotherapy n = 33 RE, 35 LE	VGB add-on therapy n = 24	TGB n = 12	CBZ n = 18	Controls n = 18
Meridian					
Right temporal	69 \pm 12 *#§	75 \pm 15*#	86 \pm 4	86 \pm 5	89 \pm 2
Range	40 - 90	38 - 90	78 - 90	70 - 90	82 - 90
Right superior	43 \pm 6*	42 \pm 8*	48 \pm 3	46 \pm 6*	53 \pm 4
Range	25 - 50	18 - 55	43 - 55	35 - 55	46 - 60
Right nasal	46 \pm 7*#	45 \pm 8*#	51 \pm 4	52 \pm 5	55 \pm 5
Range	25 - 55	21 - 55	42 - 57	45 - 65	44 - 63
Right inferior	58 \pm 9*#	59 \pm 12*#	66 \pm 6	68 \pm 3	70 \pm 1
Range	33 - 75	21 - 75	50 - 70	60 - 70	66 - 72
Left temporal	68 \pm 11 *#§	73 \pm 15*#§	87 \pm 3	86 \pm 6	88 \pm 3
Range	43 - 88	35 - 90	80 - 90	70 - 90	76 - 90
Left superior	43 \pm 7*§	43 \pm 8*	50 \pm 4	46 \pm 6*	53 \pm 4
Range	25 - 55	20 - 60	44 - 58	35 - 55	46 - 60
Left nasal	48 \pm 8*#	47 \pm 9*#	52 \pm 5	55 \pm 5	59 \pm 3
Range	25 - 65	22 - 60	42 - 59	45 - 60	53 - 63
Left inferior	57 \pm 10*#§	59 \pm 11*#	66 \pm 3	67 \pm 4	71 \pm 1
Range	30 - 73	26 - 70	60 - 71	60 - 70	67 - 73

One-way ANOVA with Scheffe's post hoc test; * p < 0.05 vs. controls, # p < 0.05 vs. CBZ, § p < 0.05 vs. TGB

5.3.1.1 Risk factors for visual field defects

The etiology of epilepsy (symptomatic vs. cryptogenic) did not influence the prevalence of visual field defects (chi square test, p = 0.06), nor the severity (mild vs. severe) of the visual field defect (chi square test, p = 0.18). Furthermore, there was no difference in prevalences between patients treated with monotherapy and those treated with add-on therapy (chi square test, p = 0.842). In the whole group of 60 patients treated with VGB, the prevalence in males was 11/25 (44%, 95 % CI 24%-64%) and in females 13/35 (37%, 95% CI 21%-53%). However, no statistical difference in the prevalence between males and females was found with the chi square test (p = 0.118). In linear regression, no significant correlation between the visual field extents and the duration of VGB therapy or the daily or cumulative dose of VGB was found. Neither body weight, age of the patients nor use of other GABAergic AEDs correlated with the visual field extents.

5.3.1.2 Prognosis of visual field defects

The follow-up of 4 to 38 months (15 ± 7 months) did not reveal any significant reversion in the constricted visual fields. Only one patient with mildly constricted visual fields in the first evaluation had normal visual fields in the follow-up examination after cessation of VGB therapy. For the group, the mean change in degrees in the cardinal meridians of the visual fields during the follow-up varied from narrowing by only 1° to widening by only 2°. The age, duration of VGB therapy or cumulative VGB dose did not influence the change in the cardinal visual field extents during the follow-up. Twenty-nine patients had discontinued VGB therapy 2 to 28 months (10 ± 6 months) before the follow-up examination; there was no significant difference in the change in visual fields between them and those who continued on VGB. The correlation in the temporal visual field of the right and left eye between the first and follow-up examination is presented in Figure 4.

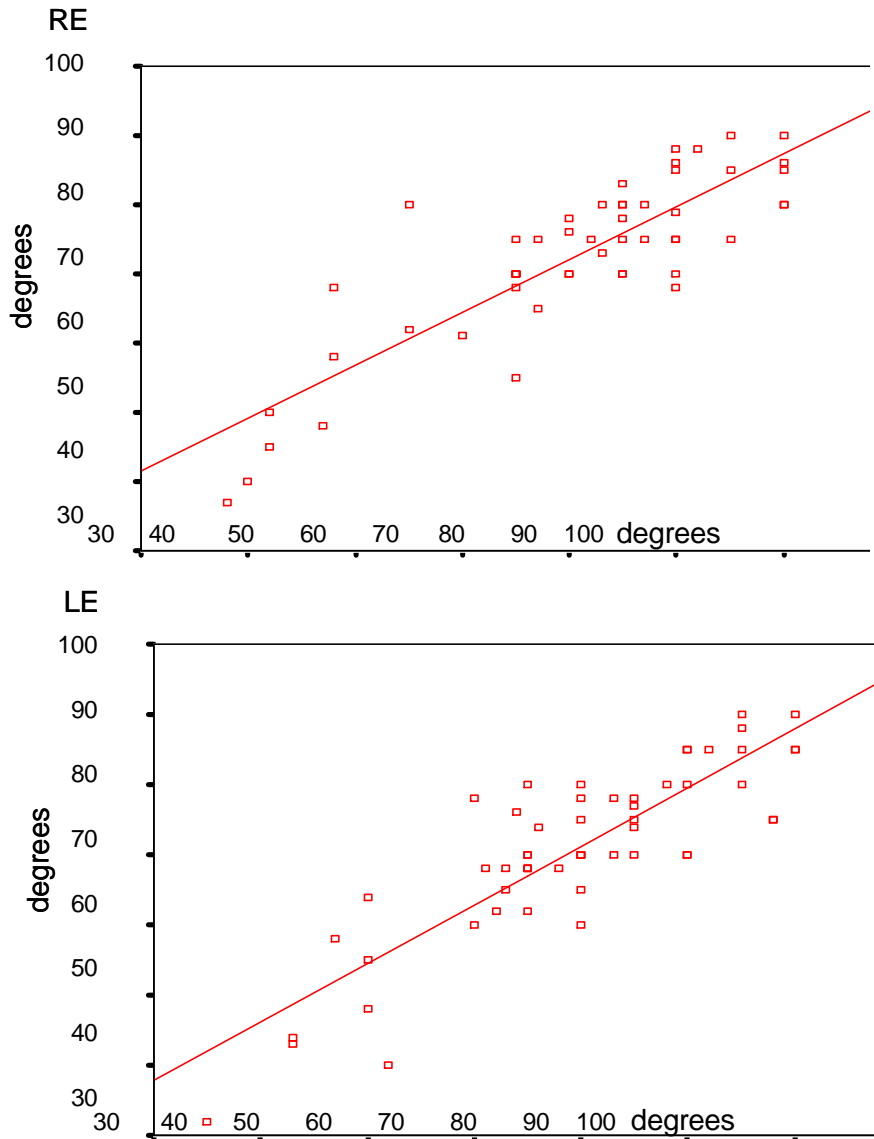


Figure 4. The change in the temporal visual field extents between the first (x-axis) and the follow-up (y-axis) examinations. The spots over the diagonal line means better and below it worse visual fields. (RE = right eye, LE = left eye).

5.3.2 Static perimetry (V)

Automated static perimetry revealed localised defects (one hemianoptic and two quadrantanoptic) in three of the 15 TGB monotherapy patients. None of the TGB monotherapy patients had concentric constriction in visual fields examined with static perimetry. The reliability criteria were within normal limits in each eye.

5.4 Contrast sensitivity (III, V)

Contrast sensitivity was within age-dependent normal values (Mäntyjärvi and Laitinen, 2001) in all patients with the exception of the patient in the TGB monotherapy group who had previously-documented optic nerve atrophy and homonymous hemianopia, and of one patient (left eye) in the VGB monotherapy group. For the group, no differences were found with the analysis of variance (one-way ANOVA with Scheffé's post hoc test) in contrast sensitivity between the patients treated with VGB, TGB or CBZ monotherapy and normal controls (the right eye: $F = 1.796$, $df = 3$, $p = 0.153$, the left eye: $F = 1.353$, $df = 3$, $p = 0.262$) (Table 9). No difference was found between the right and left eye in any therapy group. However, among the VGB monotherapy patients, positive correlation was found with linear regression between the visual field extents and contrast sensitivity values (for instance, the temporal meridian: the right eye $R = 0.498$, $p = 0.005$; the left eye $R = 0.476$, $p = 0.006$). In addition, if the results are considered according to the clinical categories of the visual fields, a significant difference ($p = 0.012$ in the right eye and $p = 0.045$ in the left eye) was revealed by the Kruskal-Wallis test in contrast sensitivity between the groups of patients with normal, mildly abnormal and severely abnormal visual fields (Figure 5).

Table 9. Contrast sensitivity with Pelli-Robson letter chart in VGB monotherapy patients, TGB monotherapy patients, CBZ monotherapy patients and in normal controls (mean \pm SD).

	VGB n = 30 RE, n = 32 LE	TGB n = 14	CBZ n = 18	Controls n = 35	p
Pelli-Robson					
Right eye	1.76 \pm 0.14	1.70 \pm 0.14	1.78 \pm 0.11	1.77 \pm 0.14	0.153
Range	1.50 - 1.95	1.50 - 1.95	1.65 - 1.95	1.65 - 1.95	
Left eye	1.74 \pm 0.19	1.68 \pm 0.12	1.78 \pm 0.13	1.80 \pm 0.12	0.262
Range	1.20 - 1.95	1.50 - 1.95	1.65 - 1.95	1.65 - 1.95	

p with one-way ANOVA

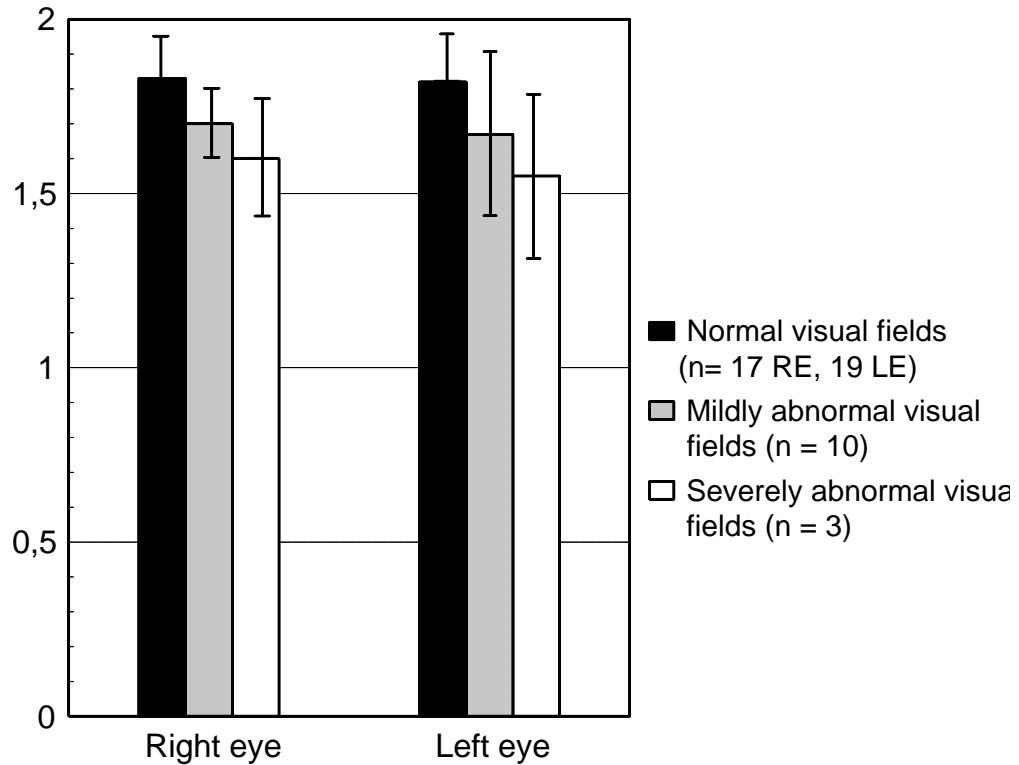


Figure 5. Contrast sensitivity in VGB monotherapy patients (mean \pm SD).

5.5 Glare sensitivity (III)

The results of macular photostress and brightness acuity tests were within the normal ranges (Glaser et al.1977) in both VGB monotherapy patients and CBZ monotherapy patients. None complained about exceptional dazzling during the examination. The patients treated with TGB did not perform glare sensitivity examinations.

5.6 Color vision (IV, V)

Abnormal color vision was found in 10 of 31 patients treated with VGB monotherapy (32%, 95% CI 16% - 48%), in 7 of 14 patients treated with TGB monotherapy (50%, 95% CI 24% - 76%), and in 5 of 18 patients treated with CBZ monotherapy (28 %, 95 % CI 7% - 49%) (Table 10). In the VGB monotherapy group, all three patients with severely constricted visual fields, five of 10 patients with mildly constricted visual fields and two of 19 patients with normal fields had color vision defects.

Two patients in the TGB monotherapy group who had abnormal color vision, had quadrantanopias on perimetry.

Table 10. The frequencies of color vision defects in VGB, TGB and CBZ monotherapy patients examined with the SPP2, FM100 and CVM712, (number of patients (%) with 95% (CI)).

	VGB (n = 31)	TGB (n = 14)	CBZ (n = 18)
SPP2	3 (10%)	1 (7%)	0 (0%)
95% CI	Upper 20%	Upper 20%	
FM100	9 (29%)	3 (21%)	3 (17%)
95% CI	13% - 45%	Upper 40%	Upper 34%
CVM 712	5 (16%)	7 (50%)	4 (22%)
95% CI	3% - 29%	24% - 76%	3% - 41%

SPP2 = Standard Pseudoisochromatic Plates part two, FM100 = Farnsworth-Munsell 100 Hue test, CVM 712 = Color Vision Meter 712 anomaloscope

5.6.1 Standard Pseudoisochromatic Plates 2

Some patients in the VGB and TGB monotherapy groups had single red-green and blue errors in the SPP2 plate test. Three patients in the VGB group and one in the TGB group missed the test. They were not deemed to be congenital defectives because errors were not symmetric, as they are in congenital color vision defects (Ichikawa et al., 1987). The patient with previously-documented optic nerve atrophy in the TGB group did not see any of the plates, and did not perform other color vision tests.

5.6.2 Farnsworth-Munsell 100 Hue test

There was a significant difference between the groups of patients treated with VGB, TGB and CBZ monotherapy and controls in the age-adjusted FM100 total error scores with ANOVA ($F = 5.494$, $df = 3$, $p = 0.002$ in the right eye, $F = 5.231$, $df = 3$, $p = 0.002$ in the left eye). Scheffe's post hoc test reveals the difference between the VGB monotherapy patients and normal controls. No difference was found between the different therapy groups or between the TGB or CBZ groups and controls

(Table 11). The errors accumulated in the third (green-blue) box in all patient groups. There was no difference in the FM100 results between the right and left eyes in any group. A blue axis was found in 4 (13%) of 31 VGB monotherapy patients, in 1 (6%) of 18 CBZ monotherapy patients, and in 2 (13%) of 14 TGB monotherapy patients. None had red-green axis.

Within the VGB group, with regard to the classification of visual fields, no difference ($p = 0.059$ in the right eye and $p = 0.068$ in the left eye) in the age-adjusted FM100 total error scores was found by the Kruskal-Wallis test between the patients with normal, mildly abnormal and severely abnormal visual fields (Figure 6).

Table 11. Age-adjusted FM100 total error scores (TES) of VGB monotherapy patients, TGB monotherapy patients, CBZ monotherapy patients and controls (mean \pm SD).

	VGB n = 29 RE n = 30 LE	TGB n = 13 RE n = 14 LE	CBZ n = 18	Controls n = 47	p
FM100 TES					
Right eye	11.7 \pm 4.5	10.9 \pm 2.6	10.5 \pm 2.3	8.9 \pm 3.0	0.002*
Range	5.2 - 21.6	7.1 - 14.1	6.9 - 15.4	2.7 - 15.0	
Left eye	12.0 \pm 4.5	10.9 \pm 2.9	10.3 \pm 2.8	9.1 \pm 2.7	0.002*
Range	6.2 - 24.4	6.0 - 14.7	6.6 - 18.3	3.8 - 14.9	

*One-way ANOVA with Scheffe's posthoc test between the VGB monotherapy patients and normal controls.

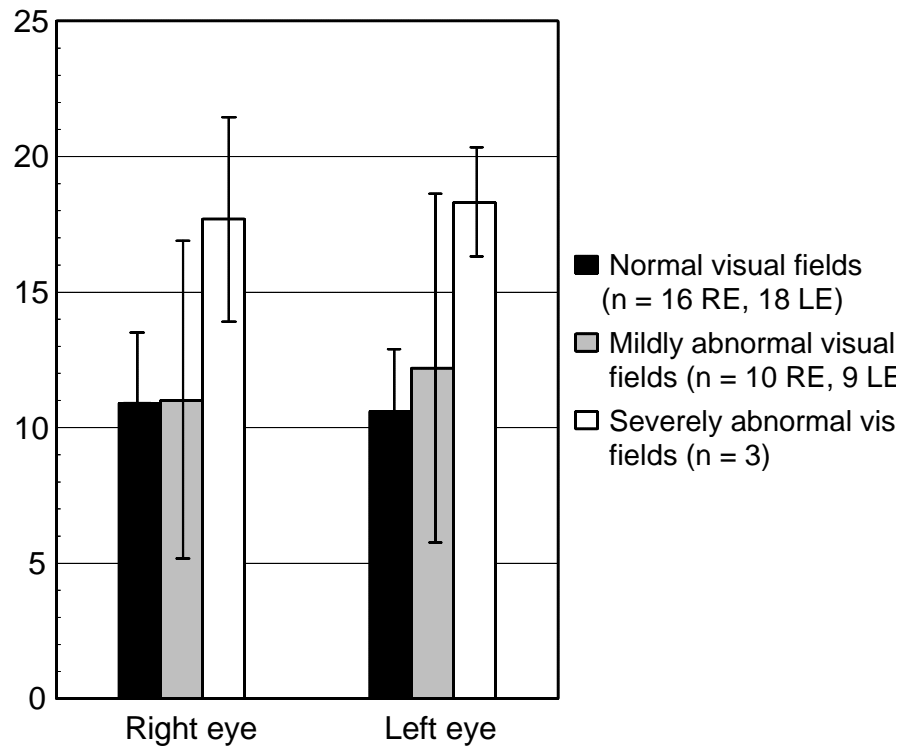


Figure 6. FM100 total error scores in VGB monotherapy patients (mean \pm SD).

5.6.3 Color Vision Meter 712 anomaloscope

Abnormal red-green AQ was found in three of 31 (10%) VGB monotherapy patients, in four of 14 (29%) TGB monotherapy patients and in three of 18 (17%) CBZ monotherapy patients, whereas abnormal blue AQ was found in two (6%) VGB patients and in one (7%) TGB patients, but not in any CBZ patients. The red-green MR was abnormally wide in three (21%) TGB patients and in two (11%) CBZ patients, but, surprisingly, was normal in all VGB patients. The blue MR was abnormal in one (3%) VGB patient, in two (14%) TGB patients and in one (6%) CBZ patient.

5.7 Dark adaptation (III)

Dark adaptation thresholds were measured in seven patients who had severely or mildly constricted visual fields; six of them were being treated with VGB monotherapy, and one with VGB add-on therapy. Only one monotherapy patient with severely constricted visual fields had slightly abnormal thresholds in the right eye: 5.2 log units for cones, 2.9 log units for rods, and 2.8 log units for the

rods in the left eye, but the time for both thresholds was normal. All others had normal dark adaptation curves.

5.8 Electroretinogram (I)

All the patients with severe visual field defects and 60% of those with mild visual field defects were found to have reduced oscillatory potentials in ERGs. Patients with severe visual field defects also had reduced amplitude of a and b waves in cone photopic and rod scotopic ERGs.

5.9 Neuroradiology (I)

All MRI of orbits, visual pathways, and occipital lobes were normal and did not reveal any new data regarding the etiology of the visual field defects.

6 DISCUSSION

6.1 Patients and controls

The unique patient population in this study provided a good opportunity to contribute to our knowledge of the effects of AEDs on visual function. Both GABAergic drugs examined, VGB and TGB, are approved for the adjunctive therapy of partial epilepsy in adults. Consequently, patients with initial or long-term monotherapy with these AEDs are difficult to find even world-wide. The patients in the present study were on monotherapy, the majority on their initial monotherapy, with the exception of VGB add-on patients in study II. On the other hand, the add-on patients made it possible to compare the prevalence rates of VGB-associated visual field defects in patients treated with monotherapy and add-on therapy. For studies I-IV, we identified patients with partial epilepsy who, at the time of diagnosis, during 1988 to 1995, were randomly assigned to either VGB or CBZ monotherapy in two clinical drug trials. They had already successfully used their initial monotherapy for 2.4 to 10 years and still attended the outpatient Department of Neurology in Kuopio University Hospital.

In the TGB study, the patient population was smaller and the patients were older than in the VGB or CBZ groups, but this also is a unique patient population world-wide since all these patients received TGB as long-term monotherapy for 1.9 to 4.6 years, after failure with their conventional AED monotherapy. However, there are methodological problems in conversion studies. Ideally, patients should only have used single monotherapy earlier, to avoid the confounding influence of different earlier treatments. Only two of the TGB monotherapy patients had received single AED monotherapy earlier: the others had received various AED monotherapies, and two had received VGB earlier. The duration of VGB therapy was short (3 and 9 months), and cumulative doses were small in both cases. The subsequent TGB monotherapy had already continued for 32 and 53 months. As it is difficult to find TGB monotherapy patients, we wanted neither to lose any of the patients nor to start to select any of the patients. In this case, as the visual fields were normal we know that these patients did not have VGB-associated visual field defects. We believe that the duration of TGB monotherapy was long enough to allow us to identify the possible TGB-associated ophthalmological adverse effects in our patients, although we cannot exclude the influence of earlier AED therapy on visual function.

Generally, the normal values for different visual function tests are measured in healthy controls, and accordingly, all controls in the present study were healthy volunteers. The best possible control population would be similar epilepsy patients without any AED therapy, to permit the

detection of the influence of seizures and epilepsy itself. However, epilepsy should always be effectively treated, as untreated epilepsy is a progressive phenomenon and repeated seizures may cause neuronal loss and cognitive decline. It is considered unacceptable for ethical reasons to conduct placebo-controlled studies if this involves leaving patients with active epilepsy untreated. Given the situation we were in at the beginning of the study, facing a possibly serious drug-induced adverse effect, it was not possible to collect a control group from among untreated epilepsy patients. Consequently, we used normal values of different parameters which had been examined over many years at our clinic in healthy volunteers, and which are used in both research and clinical work.

6.2 Ophthalmological findings

Visual acuities were normal in all patients regardless of the AED therapy used. Some patients had ophthalmological diseases which caused decreased VAs, and the affected eyes were excluded from the study. The results of the present study are in agreement with those of other studies which have reported about normal or only slightly impaired VAs (Miller et al., 1999, Johnson et al., 2000).

Surprisingly, the appearance of the retina was normal in all patients with VGB associated visual field defects. In some studies, arterial narrowing, wrinkling retinopathy, abnormal pigmentation and other nonspecific alterations have been described, but the association between these findings and visual field defects is questionable (Krauss et al., 1998, Lawden et al., 1999, Miller et al., 1999, Wild et al., 1999). In our study, some patients had retinal pigment epithelial scars from earlier central serous chorioretinopathy episodes, but no retinal abnormalities possibly attributable to VGB therapy were observed. In the present study, pallor of the optic nerve heads was observed only in the most severe cases; this finding is in line with those in other studies (Lawden et al., 1999, Wild et al., 1999). This mild optic nerve atrophy might be a consequence of ganglion cell loss, possibly secondary to cell damage in inner retinal layers. In case reports, the optic nerves and tracts of patients with VGB-associated visual field loss showed severe atrophy mainly in the peripheral retinal fibers with relative preservation of macular fibers (Buncic et al., 2001, Ravindran et al., 2001).

6.3 Visual fields

6.3.1 General aspects

The main result of the present study was that 40% of the epilepsy patients treated with VGB monotherapy or add-on therapy were found to have asymptomatic bilateral concentric visual field defects, whereas none of the TGB or CBZ monotherapy patients had similar constrictions. Three patients in the TGB group had localized defects from earlier brain lesions. The prevalence of VGB-associated visual field defects in the present study is in accordance with that reported in other studies. However, the prevalence rates in different studies range from 13 % to over 80%, the mean being 39% (95% CI 36% - 41%). This variation in prevalence rates might be partly explained by methods, i.e. automated static or manual kinetic perimetry, and the limits of normality used. There are no accepted criteria for concentric visual field defects, and changing the limit of normality does alter the prevalence rates significantly. In addition, study populations also differ from each other which can influence the rate of successful and reliable perimetry outcomes. There are probably both underestimations as well as overestimations in the previously reported prevalence rates. In several studies concerning VGB-associated visual field defects, the patients suffered from drug-resistant epilepsy and received AED polytherapy which can influence the outcome of visual field examination and other psychophysical tests because of fatigue and psychomotoric slowing. We believe that with our patient setting we were able to avoid any possible additive toxic effects of AED polytherapy. Moreover, the patients' good seizure control for years eliminates the detrimental effect of epilepsy itself on visual perception.

In the present study, the visual field defects in patients treated with VGB was severe in 13% and mild in 27% of patients. In a cohort reported by Wild et al. (1999), the corresponding rates were severe in 15%, moderate in 10% and mild in 3%, according to their categories. The patients in the present study were asymptomatic: only two patients had bumped into objects. This does not differ from findings reported in other studies (Daneshvar et al., 1999, Wild et al., 1999, Hardus et al., 2000a). Generally, concentric visual field defects, for instance in patients with retinitis pigmentosa, affects the performance of daily tasks only minimally (Szlyk et al., 2001). In the symptomatic cases reported so far, only in a minority of patients has the defect been so severe that it has restricted their daily living (Eke et al., 1997, Krauss et al., 1998, Wilton et al., 1999, Manuchehri et al., 2000). According to the criteria of the Finnish Ministry of Social Affairs and Health for visual handicap (Sosiaali- ja terveystieteiden ministeriön päätös n:o 1012, 1986), a majority of the patients, who had severe visual field defect were mildly (<50%) visually handicapped.

The extents of visual fields were significantly constricted in the VGB group as compared with those in TGB group, CBZ group or normal controls. Some authors have emphasized that VGB-associated visual field defects are predominantly nasal and concentric only in severe cases (Lawden et al., 1999, Wild et al., 1999, Midelfart et al., 2000), whereas other studies have shown that temporal fields outside of the limits of automated perimetry are also regularly affected (Miller et al., 1999, Hardus et al., 2000a,b). We found a significant difference in all meridians of visual fields between VGB patients and normal controls or CBZ patients which supports the idea that defects develop in the entire periphery of the visual field leading to concentric constriction of the visual fields. Because the hill of vision is physiologically asymmetric, this type of constriction will therefore reach the nasal border of the central 30° of static perimetry earlier than its temporal counterpart. In the follow-up of visual fields in patients treated with VGB, the temporal extent of the visual field must be examined to at least 70°. If minimal visual field changes in the periphery are ignored, a false impression of normal field may result (Midelfart et al., 2000, Schiefer et al., 2000, Hardus et al., 2001a). Pre-existent visual field defects associated with epilepsy or with background brain pathology may cause false positive findings, but the worsening of a pre-existing defect might also be overlooked. Certain individuals need several training perimetries before producing reliable fields on automated static perimetry. Peripheral depressions and an unaffected central field are typical findings in an inexperienced testee (Wild et al., 1991, Olsson et al., 1997).

6.3.2 Methodology

The ideal visual field test would be easy to perform and 100% reliable, but unfortunately, we have no such test. In recent years, we have learned to rely almost completely on automated tests in clinical routines. In the present study, kinetic perimetry with the Goldmann perimetry was chosen to test the full limit of peripheral vision, as earlier reports had described concentrically constricted fields in patients taking VGB (Eke et al., 1997). When the present study was begun, we had no knowledge about the capability of automated perimetry of 30o to detect incipient concentric constriction in the peripheral visual field. To minimize variability on the part of the examiners, the same ophthalmologist (the author) calibrated the Goldmann perimeter and investigated all the patients during the study. To confirm our first results, repeated visual field examinations were performed within a few months in all VGB and CBZ monotherapy patients, and some of the VGB patients underwent an additional

neuro-ophthalmological examination including kinetic perimetry at Turku University Hospital. An independent neuro-ophthalmologist (Professor Eeva Nikoskelainen) verified the findings.

We believe that the possibility of conversion-reaction or malingering as a cause for visual field defects is excluded in the present study. Unlike malingering patients, none of the patients with visual field defects had clinical symptoms, or demands for financial compensation at the time when the visual field loss was detected. The appearance of kinetic visual fields was not typical for conversion (Trauzettel-Klosinski, 1997); visual fields were not spiraling, constriction was visible in all examined isopters, and there were no crossing isopters. During the examination, the size of the isopters was randomly checked again, and after the kinetic perimetry, the visual field constriction was verified with careful confrontation at different distances.

The Goldmann perimetry has been found to be a reliable method in patients with neurologic diseases (Li et al., 1978, Beck et al., 1985, Manji and Plant, 2000). The benefit of testing visual fields with the Goldmann perimeter is that the operator can give guidance and encouragement to the subject and tailor the test to the cognitive and attention level of the subject. In automated perimetry, the testing procedure is conducted by the computer with a limited influence by the operator, and this has been shown to be too demanding and fatiguing for some patients, causing false abnormal results. In addition, it is conceivable that 30o static perimetry alone may not detect all VGB-associated visual field defects (Wild et al., 1999, Schiefer et al., 2000). Newly designed short perimetric programs (for instance, the Swedish Interactive Testing Algorithm (SITA) by Humphrey) may be performed successfully and may be more reliable even in children and patients with learning difficulties (Morales et al., 2001).

6.3.3 Risk factors for visual field defects

Linear regression analysis did not reveal any correlation between visual field extents and duration of VGB therapy, VGB dosage, or cumulative dose of VGB consumed during the treatment. The evaluations of the cohorts by Marketing Authorization Holders (CPMP report /1357/99) and Wild et al. (1999) have, however, found an increase in the cumulative incidence within the first 2 kg of VGB intake and within 3 to 4 years of treatment. In studies where a positive correlation was found between the duration of VGB therapy and visual field defects, or between the cumulative dose of VGB and visual field defects, the mean duration of VGB therapy was 3 years (Hardus et al., 2001a) and 6 years (Manuchehri et al., 2000), and the cumulative dose <2kg (Hardus et al., 2001a) and 3.6 kg (Manuchehri et al., 2000). The probable explanation for our result is that majority of our patients

had received VGB for so long that the cumulative doses of VGB were so high that it was impossible to detect the threshold effect.

In the present study, males had a slightly increased prevalence for visual field defects (44% in males vs. 37% in females), but the difference does not reach statistical significance. As earlier studies have shown that male gender carries an approximately two-fold increased risk for VGB associated visual field defect (Arndt et al., 1999a, Wild et al., 1999, Hardus et al., 2000a, Manuchehri et al., 2000, Hardus et al., 2001a), the retinal toxicity of VGB presented as an all or none response might be genetically based affecting males more frequently than females.

It has been suggested that combination therapy with other AEDs and VGB is more toxic to retina than monotherapy (Harding, 1997, Arndt et al., 1999a) but this suggestion has been criticized (Hirsch, 2000). Other GABAergic drugs in particular have been suspected but no studies have been published to confirm this hypothesis. We did not find more visual field defects in epilepsy patients treated with polytherapy than with monotherapy. Neither did we find differences in visual field extents between those patients who used other GABAergic AEDs, gabapentin or topiramate in addition to VGB and those who used other AEDs. However, in view of the small number of patients involved, we cannot exclude their influence. Visual field constriction during treatment with another GABAergic AED, progabide, has only been described in one patient (Baulac et al., 1998). Recently, Lindberger et al. (2000) did not find visual field defects in epilepsy patients with gabapentin therapy in a study of gabapentin versus VGB as first add-on, in which standardized perimetry examination was offered all patients at the end of the study.

6.3.4 Prognosis of visual field defects

Study II showed that VGB-associated concentric visual field defects are not reversible. This finding is consistent with that of other groups (Hardus et al. 2000b, Johnson et al., 2000 and Paul et al., 2001). Anecdotal reports of reversed visual field defects have been presented (Versino et al., 1999, Giordano et al., 2000, Krämer et al., 2000) but no significant improvement in visual fields has been published in larger series. Improvement in visual fields in repeated examinations must be interpreted with caution due to the learning effect (Wild et al., 1991, Vanhatalo et al., 2001). In the present study, only one patient showed clear improvement from mildly constricted fields in the first examination to normals in the follow-up. It was not possible to identify progressive deterioration in the visual field constriction with continued therapy, and there was no evidence to suggest a recovery

when VGB was discontinued. This supports the case reports and studies published so far (Hardus et al., 2000b, Johnson et al., 2000, Malmgren et al., 2001, Paul et al., 2001). Neither the age of the patients, the duration of VGB therapy nor the cumulative dose of VGB correlated with the change in visual field extents during the follow-up. At present, the data suggest that VGB-associated visual field defects are at least long-standing if not permanent.

6.4 Contrast sensitivity

The results of contrast sensitivity examinations were within normal ranges in most patients regardless of the AED therapy received when compared with our age-dependent normal values. However, a correlation between contrast sensitivity and visual field extents in patients treated with VGB was found. The patients with constricted visual fields had significantly lower contrast sensitivity values, which probably indicates retinal toxicity of VGB. It has been hypothesized that GABA is involved in the center-surround antagonism at the level of amacrine and horizontal cells (Falk, 1991, Harris et al., 1995) which is an important function in contrast sensitivity. In the study by Sartucci et al. (1997), add-on therapy with VGB had beneficial effect on the contrast sensitivity in patients with refractory epilepsy. Their study showed a constant and progressive recovery of contrast sensitivity after adding VGB on CBZ monotherapy, the most prominent changes being in the intermediate frequencies. Better seizure control with a more efficient treatment regimen as well as the learning effect might explain their results.

The weakness in the methodology of the present study is that only one spatial frequency (3cpd) was tested. However, intermediate spatial frequencies from 3 to 5 cpd are the peak contrast sensitivity and have been suggested to be the most important feature of contrast sensitivity function in everyday tasks such as reading. In two studies regarding the effect of GABAergic drugs, midazolam and lorazepam, on contrast sensitivity function in healthy volunteers, the most prominent impairment after administration of these drugs was in the low to intermediate spatial frequencies (Blin et al., 1993, Harris et al., 1995). The method used in this study, the Pelli-Robson letter chart, has been found to be reliable in detection of intermediate spatial frequency sensitivity loss (Rubin et al., 1988). Thus, it can sufficiently reveal the changes in the contrast sensitivity caused by the AEDs evaluated in the present study. In a recent study regarding performance in daily tasks of patients with retinitis pigmentosa, Szlyk et al. (2001) found that patients whose Pelli-Robson contrast sensitivity

was greater than 1.4 had mild or no difficulties in reading, mobility and peripheral detection. Most of the patients in the present study exceeded this limit.

6.5 Glare sensitivity

In contrast to studies by Bayer (1991) and Bayer et al. (1995a,b), we found no enhanced glare sensitivity in VGB nor in CBZ patients. We measured glare sensitivity in photopic conditions and with high contrast, while Bayer used a Rodenstock Nyktometer with mesopic light and low contrast, which is probably more sensitive to minimal changes in glare sensitivity. The normal results of macular photostress tests support the findings of other investigators that VGB's retinotoxic influence is directed more to peripheral than to central retina. Macular photostress and brightness acuity tests were not carried out in study V, so the possible effect of TGB on glare sensitivity remains unclear.

6.6 Color vision

In the present study, acquired red, green and blue color vision defects was associated with AED therapy regardless of the drug used. The defects resembled tritan-like Verriest type III mixed blue and red-green defect (Hart, 1987) in the majority of the patients, but there were also both predominantly tritan and deutan defects. An abnormally high total error score was found in 9 of 31 (29%) VGB monotherapy patients. Bayer (1991) reported a prevalence rate as high as 65% in VGB add-on patients using the same normal values of Verriest et al. (1982) as we did. However, the superimposed effect of polytherapy in his patients cannot be excluded. The results in recently published papers concerning VGB-associated visual field defects and color vision are not comparable with ours because of the different method used. In the present study, patients treated with VGB had color vision defects in association with the visual field defects, which supports the idea of retinotoxicity as a cause of the visual field defects.

The present study is the first one regarding the effects of TGB on color vision, and it seems that TGB can also cause color vision defects in a large number of cases. However, earlier AED monotherapy can affect color vision as well, although the patients concerned had received TGB already for 2 to 4.5 years as monotherapy. Normal aging changes, such as subtle lens opacities, may be confounding factors; the TGB monotherapy patients in the present study were older than those in

the VGB and CBZ groups. However, on the basis of the effects of nicotinic acid in GABAergic transmission in the animal retina (Perlman and Normann, 1990), it is possible that TGB might interfere with color perception. Future evaluation of color vision in epilepsy patients treated with initial TGB monotherapy will give us more information about the issue.

In CBZ patients, we found color vision defects in 3 of 18 (17%) with the FM100 Hue test. Recently, Lopez et al. (1999) found abnormal color vision with binocularly performed FM100 in 67% of epilepsy patients treated with CBZ monotherapy. Our results are in line with the findings of other investigators (Paulus et al., 1996, Bayer, 1991, Bayer et al., 1991a,b, Bayer et al., 1997) who have reported elevated FM100 total error scores and accumulation of errors along blue axis in CBZ monotherapy patients.

The methods we used in color vision measurements were conventional, commercially available tests, and the conditions were standardized with respect to illumination. All examined eyes had good visual acuity and none of the patients were taking medications affecting color vision other than AEDs. FM100 seems to reveal most reliably color vision defects, while SPP2 and CVM 712 anomaloscope, although the tests with them are short and easy to perform, do not seem to be valuable in screening possible retinotoxicity of AEDs.

6.7 Dark adaptation

It was rather surprising that dark adaptation curves were normal in patients with VGB associated visual field defects. This finding is consistent with those of other investigators who have also found normal dark adaptation thresholds in patients with severely constricted visual fields (Bayer 1991, Ruether et al., 1998, Besch et al., 2000). The method used in the present study, the Goldmann-Weekers adaptometer records rod thresholds in the paracentral area (at a distance of 18° from the fovea centralis). It is possible that the retinal network in that part of the retina is not damaged by VGB to the extent which is observable in the conventional dark adaptation examination.

6.8 Electroretinogram

The ERG is a sensitive and objective tool for detecting toxic effects on the retina. In the present study, electrophysiologic results were available only in a minority of patients treated with VGB and not at all in patients on TGB or CBZ. All patients with VGB-associated visual field defects who underwent ERG examination had similar changes to those reported in other studies (Arndt et al., 1999a, Krauss et al., 1998, Harding et al., 2000b). In the context of VGB-associated retinal toxicity, the confounding effect of increased retinal GABA levels on ERG even in patients without visual field defects might diminish its worth in diagnosis and follow-up of patients on VGB therapy (Duckett et al., 1998, Brigell, 1998, Harding et al., 2000a, Hardus et al., 2001b). On the other hand, electrophysiological markers have been suggested to indicate the mechanism responsible for the visual field defects, and might be used before the field loss becomes established. According to results in ERG and EOG, the site of retinal dysfunction has been identified in the amacrine and Müller cells in the inner retina (Harding et al., 2000b, Coupland et al., 2001, Hardus et al., 2001b), in the cones (Krauss et al., 1998, Miller et al., 1999, Ponjavic and Andréasson, 2001), and in the outer retinal layers (Arndt et al., 1999a) but the exact mechanism of the dysfunction has not been elucidated with electrophysiological examinations.

6.9 Possible explanations for VGB-associated visual dysfunction

Since the first detection of VGB-attributed visual field constriction, many speculations about the mechanism of the phenomenon have been presented, but no convincing mechanism for VGB's retinal toxicity has been published in studies conducted to date.

Epilepsy itself and the detrimental effects of AED polytherapy have been suggested to play a causative role in the occurrence of visual field defects (Wilson and Brodie, 1997, Harding, 1997). It was assumed that the outcome in visual field testing might have been influenced by fatigue and psychomotoric slowing caused by the high frequency of seizures, underlying severe brain pathologies, and AED polytherapy in patients with drug-resistant epilepsy (Backström et al., 1997, Harding, 1997, Arndt et al., 1999a). VGB has not been found to cause deterioration in cognitive function, attention or concentration evaluated by neuropsychological tests (Saletu et al., 1986, Dodrill et al., 1993, Ylinen et al., 1995). On the contrary, patients with clinically successful VGB monotherapy performed better on retrieval from delayed verbal memory, flexibility of mental processing, and psychomotor

speed when compared with patients receiving CBZ (Kälviäinen et al., 1995). In the present study, the patients who had visual field defects were seizure-free and had normal general intelligence and concentration ability verified by formal neuropsychological testings. Thus, detrimental cognitive effects of epilepsy itself or AED therapy do not seem to be the probable explanation for VGB-associated visual dysfunction.

Visual dysfunction with the use of VGB has been attributed to elevated levels of retinal GABA which has been suspected to be toxic to GABAergic cells in the retina (Krauss et al., 1998, Harding et al., 2000a, Coupland et al., 2001). Highly elevated levels of retinal GABA after administration of VGB have been shown in several animal studies (Neal et al., 1989 and 1990, Cubells et al., 1987, Sills et al., 2001), but the toxic effects of extra GABA in the retina are not known. Generally, released GABA is rapidly removed by uptake mechanisms and metabolized in glial cells or presynaptic neurons. The effects of elevated retinal GABA on ERG have been shown in several studies (Kupenova et al., 1991, Arnarsson and Eysteinnsson, 1997), but whether this is the same as the mechanism which causes the visual field defects is not known (Duckett et al., 1998, Harding et al., 1999, 2000a,b, Brigell et al., 2000). If this hypothesis is correct, then other compounds that affect CNS GABA levels could potentially cause similar visual disturbances in susceptible patients (Beran et al., 1998, 1999). However, Sills et al. (2001) have shown that TGB does not elevate retinal GABA in a similar manner to VGB. On the basis of the results of the present study, the GABAergic mechanism of action per se is not critical in the development of visual field defects.

Accumulation of VGB molecules in the rat retina have been shown by Sills et al. (2001). The dose-related VGB concentrations were significantly higher (300%-800%) in the retina than in brain tissues. Moreover, active transport and accumulation of immunolabelled VGB in the amacrine and Müller cells have also been found in animals (Pow et al., 1996, Crook and Pow, 1997). In humans, histopathological examination of the retina of an epilepsy patient with VGB-associated visual field defects suggested that the primary site of injury lies within the ganglion cells, although both INL and ONL presented loss of nuclei (Ravindran et al., 2001). This VGB accumulation hypothesis needs more data in different species, and also additional examinations of available human specimens.

Hosking et al. (2001) showed that ocular blood flow is reduced in epilepsy patients treated with VGB when compared with epilepsy patients treated with conventional AEDs or normal controls. They suggested that this reduced ocular perfusion may have implications in the impairment of visual functions associated with VGB. This hypothesis is based on the finding that epilepsy patients treated with VGB have also exhibited reduced cerebral blood flow (Spanaki et al., 1999).

6.10 Implications for clinical practice

Epilepsy is a disease which can be lethal in patients with uncontrolled seizures, and requires long-term, even life-long therapy. The goals of AED therapy are to control seizures and to improve the patient's quality of life without subjecting the patient to untoward effects of the therapy. All AEDs pose some risk for ophthalmological problems, as does uncontrolled epilepsy itself.

VGB is currently marketed in over 65 countries world-wide. In the USA, VGB has not had marketing authorization and after the risk of visual field defects was discovered the manufacturer of VGB received an "unapprovable" letter for VGB in 1998 from the Food and Drug Administration. In 1999, the Committee for Proprietary Medicinal Products of the European Agency for Evaluation of Medicinal Products (EMA) in their opinion regarding the risk related to visual field defects, recommended the maintenance of the marketing authorizations for VGB only under specific conditions in the European Union (CPMP-report/1357/99). VGB should currently be used only in combination with other AEDs for patients with resistant partial epilepsy in situations where all other appropriate drug combinations have proved inadequate or have not been tolerated. Currently, the benefits of treating infantile spasms with VGB monotherapy seem to outweigh the risks, but further prospective studies and follow-up of children are needed to evaluate the place of VGB in this indication (Vigabatrin Advisory Group, 2000).

If VGB is used, visual field examination should be performed before the start of treatment and at regular intervals during treatment. The relationship between the duration of exposure to VGB and the development of the field defect is largely unknown; six-month intervals have been suggested for the follow-up, but there is no current clinical evidence to support this or any other interval. More data are needed to determine the clinical course of VGB-associated visual field defects in order to determine the proper follow-up interval. Confrontation testing does not reliably identify the defect. The visual change does not typically involve the central visual field and therefore remains asymptomatic in a majority of cases.

Visual field examination should be performed under standardized, repeatable and comparable conditions using a Goldmann kinetic perimeter, or a Humphrey or corresponding static perimeter. The temporal extent must be examined to at least 70°. Any new visual field defect that is not previously documented should be subject to a repeat assessment. VGB-attributed visual field defects might be overlooked in patients with visual field defects from other causes. Patients with pre-existent visual field defects due to other causes should not be treated with VGB. Reliable assessment of visual fields in children over 9 years of developmental age is possible with perimeter, especially with a

Goldmann kinetic perimeter. Reliable assessment of visual fields in children less than 9 years of developmental age is seldom possible. Other methods, such as ERGs and field-specific VEPs, have not yet been validated in the diagnosis or exclusion of VGB attributed visual field defects. Methodological limitations in the follow-up must be taken into account when evaluating the risk-benefit profile of VGB as add-on treatment in partial epilepsy in young children.

The risk of visual dysfunction must be balanced with the improvement in quality of life in patients whose seizures are controlled by VGB. Severely constricted visual fields limit the ability of the patients to perform activities of daily living, especially motility, but most of the patients with VGB-associated visual field defects are unaware that they have any visual deficits. One specific risk in epilepsy patients who are seizure-free concerns the implications of a visual field defect for driving (Manji and Plant, 2000). The visual field requirement for a driving licence in the EU demands a field (corresponding Goldmann III/4 spot size) extending at least 120° horizontally and 20° from the central fixation point above and below.

Patients who currently are well-controlled with VGB and have been treated for years with the drug without developing the visual field defect should be informed of the risk. They should also be told about the limited data which currently suggest that the defect is unlikely to develop if perimetry gives normal results after more than three years of treatment. Therefore, it seems to be acceptable to continue VGB in a majority of the patients, as long as there is adequate follow-up. In our series, the outcome of patients after discontinuation of VGB was good, with only one patient with normal fields having to be put back on VGB due to difficult seizure relapse and adverse effects with other AEDs. One patient with a severe visual field defect needed polytherapy before she became seizure-free again, although she had been totally seizure-free with VGB monotherapy for several years. Other monotherapy patients were successfully treated with other AED monotherapies, and in a few cases treatments could be totally stopped. Most of the add-on patients retained good seizure control with other treatment options, and moreover, some patients with originally refractory epilepsy became well-controlled after VGB was switched to other add-on AEDs.

VGB has been widely used in the treatment of infantile spasms and many specialists regard it as the drug of choice especially for infants with definite or possible tuberous sclerosis (Appleton, 1998, Osborne et al., 1999, Vigabatrin Advisory Group, 2000, 2001). Limited data also suggest that VGB could be withdrawn without relapse in infants who have been spasm-free for six months. However, it has been suggested that VGB should not be used as the first choice in the treatment of infantile spasms (Gross-Selbeck, 2000, Riikonen, 2000, Prasad et al., 2001, Lux et al., 2001). Follow-up of children treated with VGB as infants is needed to evaluate the place of VGB in this case. Currently,

VGB remains the drug of choice for short-term treatment of infantile spasms.

6.11 Future studies

The present study contributes to our knowledge of the retinal toxicity of AEDs. Our results confirm the causative role of VGB in the development of concentric visual field defects in association with impaired visual function in some users. Longer follow-up studies are needed to discover the long-term outcome of VGB-associated visual field defects after cessation of therapy, and the evolution of visual function during continued therapy. However, the most important challenge in the future is to elucidate the pathophysiological mechanism(s) behind VGB-associated visual field defects. The elucidation of the exact mechanism of VGB's retinal toxicity may enlarge our knowledge and understanding about the function of the complex neuronal network of the human retina.

7 CONCLUSIONS

1. Only patients treated with VGB monotherapy have bilateral concentric visual field defects. The extents of the visual fields were significantly constricted in patients treated with VGB monotherapy as compared with the visual field extents in CBZ monotherapy patients or healthy controls. Treatment with VGB causes asymptomatic bilateral concentric visual field defects. (I)
 - a) The overall prevalence of concentric visual field defects is 40% in both VGB monotherapy patients and in add-on patients. The constriction is severe in 13% and mild in 27%. (I, II)
 - b) The visual field defects are neither reversible after cessation of the drug nor progressive with continued treatment. Some patients may have improvement in their visual fields after stopping the drug. (II)
 - c) The daily or cumulative dose of VGB, duration of treatment, age, gender or body weight of the patients, or administration of other GABAergic AEDs do not correlate with the visual field constriction. According to the literature, however, male gender, cumulative dose of 2 kg of VGB and duration of treatment for 3 years have been shown to be risk factors. (I, II)
 - d) Color vision and contrast sensitivity are significantly impaired in patients who have VGB associated visual field defects, which supports the idea of the retinal toxicity of VGB. VGB does not affect glare sensitivity. (III, IV)
2. Another GABAergic AED, TGB, does not cause concentric visual field defects in the same way as VGB. Visual field defects associated with the use VGB are not a class effect of GABAergic AEDs. (V)
3. Treatment with both TGB and CBZ causes acquired color vision defects in some patients. Contrast sensitivity is not affected by TGB and CBZ. (III-V)

8 REFERENCES

- Anderson DR. Perimetry with and without automation. St. Louis, Mosby Company 1987.
- Appleton RE. Guideline may help in prescribing vigabatrin. *BMJ* 1998;317:1322. Letter.
- Arnarsson A, Eysteinnsson T. The role of GABA in modulating the *Xenopus* electroretinogram. *Visual Neuroscience* 1997;14:1143-1152.
- Arndt CF, Derambure P, Defoort-Dhellemmes S, Hache JC. Outer retinal dysfunction in patients treated with vigabatrin. *Neurology* 1999a;52:1201-1205.
- Arndt CF, Derambure P, Defoort S, Hache JC. Is visual impairment related to vigabatrin reversible? *Epilepsia* 1999b;40:S256.
- Arteaga R, Herranz JL, Valdizán EM, Armijo JA. γ -vinyl GABA (vigabatrin): Relationship between dosage, plasma concentrations, platelet GABA-transaminase inhibition, and seizure reduction in epileptic children. *Epilepsia* 1992;33:923-931.
- Backstrom JT, Hinkle RL, Flicker MR. Manufacturers have started several studies. *BMJ* 1997;314:1693.
- Baulac M, Nordmann JP, Lanoé Y. Severe visual-field constriction and side-effects of GABA-mimetic antiepileptic agents. *Lancet* 1998;352:546.
- Bayer A. Retinale Funktionsstörungen bei Patienten unter antikonvulsiven Therapie (medical thesis). Tübingen; University of Tübingen 1991.
- Bayer A, Zrenner E, Theil HJ, Paulus W, Ried S, Schmidt D. Antiepileptic drugs: Ocular side effects and a new method of measuring toxicity. *Epilepsia* 1991a;32:S86. Abstract.
- Bayer A, Zrenner E, Paulus W. Colour vision deficiencies induced by the anticonvulsants phenytoin and carbamazepine. In: Drum B, Moreland JD, Serra A eds. *Colour Vision Deficiencies X. Proceedings of the Tenth Symposium of the International Research Group on Colour Vision Deficiencies*; 1989 June 25-28; Cagliari, Italy. Dordrecht: Kluwer Academic publisher, 1991b:599-604. (*Doc Ophthalmol Proc Ser*;54).
- Bayer A, Thiel HJ, Zrenner E, Paulus W, Ried S, Schmidt D. Empfindliche sinnesphysiologische Testmethoden für oculäre Nebenwirkungen von Medikamenten am Beispiel verschiedener Antiepileptika. *Ophthalmologie* 1995a;92:182-190.
- Bayer A, Thiel HJ, Zrenner E, Paulus W, Ried S, Schmidt D. Farbsinnstörungen und erhöhte Blendungsempfindlichkeit unter Phenytoin- und Carbamazepintherapie. *Nervenarzt* 1995b; 66:89-96.
- Bayer A, Thiel HJ, Zrenner E, Dichgans M, Kuehn M, Paulus W. Color Vision test for early detection of antiepileptic drug toxicity. *Neurology* 1997;48:1394-1397.
- Beck RW, Bergstrom TJ, Lichter PR. A clinical comparison of visual field testing with a new

automated perimeter, the Humphrey Field Analyser, and the Goldmann perimeter. *Ophthalmology* 1985;92:77-82.

Beck RW. Reply to article "Vigabatrin-associated retinal cone dysfunction". *Neurology* 1998;51:1778-1779. Letter.

Benozzi JL, Jaliffa C, Nabum P, Kochen S, Gigante B, Saidon P, Rosenstein RE. Visual alterations in Argentinean patients receiving vigabatrin. *Invest Ophthalmol Vis Sci* 2001;42:S65. Abstract.

Beran R, Currie J, Sandbach J, Plunkett M. Visual field restriction with new antiepileptic medication. *Epilepsia* 1998;39:S6. Abstract.

Beran R, Hung A, Plunkett M, Currie J, Sachinwalla T. Predictability of visual field defects in patients exposed to GABAergic agents, vigabatrin, or tiagabine. *Neurology* 1999;52:A249. Abstract.

Besch D, Safran AB, Kurtenbach A, Apfelstedt-Sylla E, Dietrich TJ, Asenbauer C, Dennig D, Zrenner E, Schiefer U. Visual field defects and inner retinal dysfunction associated with vigabatrin. *Invest Ophthalmol Vis Sci* 2000; 41:S892. Abstract.

Bill PA, Vigonius U, Pohlmann H, Guerreiro CAM, Kochen S, Saffer D, Moore A. A double-blind controlled clinical trial of oxcarbazepine versus phenytoin in adults with previously untreated epilepsy. *Epilepsy Res* 1997; 27: 195-204.

Birch J, Chisholm I, Kinnear P, Pinckers A, Pokorny J, Smith V, Verriest G. Clinical testing methods. In: Pokorny J, Smith V, Verriest G, Pinckers A, ed:s *Congenital and acquired color vision defects*. New York: Grune&Stratton 1979;83-135.

Bjelajac A, Gautam M, Logan WJ. Vigabatrin and ophthalmologic abnormalities in pediatric patients. *Neurology* 1999;52:A236. Abstract.

Blackwell N, Hayllar J, Kelly G. Severe persistent visual constriction associated with vigabatrin. Patients taking vigabatrin should have regular visual field testing. *BMJ* 1997;314:1694. Letter.

Blin O, Mestre D, Paut O, Vercher JL, Aubert C. GABAergic control of visual perception in healthy volunteers: effects of midazolam, a benzodiazepine, on spatio-temporal contrast sensitivity. *Br J Clin Pharmacol* 1993;36:117-124.

Borden LA, Murali Dhar TG, Smith KE, Weinshank RL, Branchek TA, Gluchowski C. Tiagabine, SK&F 89976-A, CI-966, and NNC-711 are selective for the cloned GABA transporter GAT-1. *Eur J Pharmacol* 1994;269:219-224.

Brigell MG, Arbor A, Wild JM, Ruckh S. The effect of vigabatrin on visual function: data from a long-term open-label add-on trial in patients with uncontrolled partial seizures. *Neurology* 2000;54:A308. Abstract.

Brinton G, Norton E, Zahn J, Knighton R. Ocular quinine toxicity. *Am J Ophthalmol* 1980;90:403-410

Brodie MJ, Richens A, Yuen AWC. Double-blind comparison of lamotrigine and carbamazepine in newly diagnosed epilepsy. *Lancet* 1995; 345: 476-479.

Buncic JR, Westall, CA, Perron A, McKeen L, Munn J. Childhood optic atrophy developing after Vigabatrin-therapy. Proceedings of the 5th Meeting of the European Neuro-Ophthalmological Society EUNOS 2001, July 22.-26, 2001. Tuebingen, Germany. *Neuro-ophthalmology* 2001;25 (Suppl):97. Abstract.

Butler WH, Ford GP, Newberne JW. A study of the effects of vigabatrin on the central nervous system and retina of Sprague-Dawley and Lister-Hooded rats. *Toxicol Pathol* 1987;15:143-148.

Butler WH. The neuropathology of vigabatrin. *Epilepsia* 1989;30(Suppl 3):S15-S17.

Cannon DJ, Butler WH, Mumford JP, Lewis PJ. Neuropathological findings in patients receiving long-term vigabatrin therapy for chronic intractable epilepsy. *J Child Neurol* 1991a;6:17-24.

Cannon DJ, Weller RO, Mumford JP. No vigabatrin-induced microvacuolation in human brains: further neuropathologic investigations. *Epilepsia* 1991b;32:S12-S13. Abstract.

Carr RE, Heckenlively JR. Hereditary pigmentary degenerations of the retina. In: Tasman W, Jaeger EA eds. *Duane's clinical ophthalmology*. Philadelphia: Lippicott-Raven Publishers 1996;Vol 3;24:1-28.

Celesia GG, Bodis-Wollner I, Chatrian GE, Harding GFA, Sokol S, Spekreijse H. Recommended standards for electroretinograms and visual potentials. Report of an IFCN committee. *Electroenceph Clin Neurophysiol* 1993;87:421-436.

Chadwick DW, Marson T, Kadir Z. Clinical administration of new antiepileptic drugs: an overview of safety and efficacy. *Epilepsia* 1996; 37: S17-S22.

Chadwick D. Safety and efficacy of vigabatrin and carbamazepine in newly diagnosed epilepsy: a multicenter randomised double-blind study. *Lancet* 1999;354:13-19.

Cohen JA, Fisher RS, Brigell MG, Peyster RG, Sze G. The potential for vigabatrin-induced intramyelinic edema in humans. *Epilepsia* 2000;41:148-157.

Collins SD, Brun S, Kirstein YG, Sommerville K. Absence of visual field defects in patients taking tiagabine (Cabitril®). *Epilepsia* 1998;39:S146-S147. Abstract.

Commission on Classification and Terminology of the International League Against Epilepsy. Proposal for revised classification of epilepsies and epileptic syndromes. *Epilepsia* 1989; 30: 389-399.

Commission on antiepileptic drugs of the International League Against Epilepsy. Guidelines for therapeutic monitoring on antiepileptic drugs. *Epilepsia* 1993;34:585-587.

Committee for proprietary medicinal products. Opinion following an article 12 referral. Vigabatrin.

(CPMP-report/1357/99). The European Agency for the Evaluation of Medicinal Products, 1999, <http://www.emea.eu.int/pdfs/human/phv/135799en.pdf>. 26.10.2001.

Coupland SG, Zackon DH, Leonard BC, Ross TM. Vigabatrin effect on inner retinal function. *Ophthalmology* 2001;108:1493-1496.

Cramer JA, Fisher R, Ben-Menachem E, French J, Mattson RH. New antiepileptic drugs: Comparison of key clinical trials. *Epilepsia* 1999;40:590-600.

Crofts K, Brennan R, Kearney P, O'Connor G. Vigabatrin-induced optic neuropathy. *J Neurol* 1997;10:666-667.

Crook DK, Pow DV. Analysis of the distribution of glycine and GABA in amacrine cells of the developing rabbit retina: A comparison with the ontogeny of a functional GABA transport system in retinal neurons. *Visual Neuroscience* 1997;14:751-763.

Crooks J, Kolb H. Localization of GABA, glycine, glutamate and tyrosine hydroxylase in the human retina. *J Comp Neurol* 1992;315:287-302.

Cubells JF, Blanchard JS, Makman MH. The effects of in vivo inactivation of GABA-transaminase and glutamic acid decarboxylase on levels of GABA in the rat retina. *Brain Res.* 1987;419:208-215.

Dalby NO. GABA-level increasing and anticonvulsant effects of three different GABA uptake inhibitors. *Neuropharmacology* 2000;39:2399-2407.

Daneshvar H, Racette L, Coupland SG, Kertes PJ, Guberman A, Zackon D. Symptomatic and asymptomatic visual loss in patients taking vigabatrin. *Ophthalmology* 1999;106:1792-1798.

Danias J, Brodie S. Delayed quinine toxicity mimicking open angle glaucoma. *Br J Ophthalmol* 2001;85:238 Letter.

Dieterle L, Becker EW, Berg PA, Berkenfeld R, Reinshagen G. Allergisches Vaskulitis durch Vigabatrin. *Nervenarzt* 1994;65:122-124.

Dodrill CB, Arnett JL, Sommerville KW, Sussman NM. Evaluation of the effects of vigabatrin on cognitive abilities and quality of life in epilepsy. *Neurology* 1993;43:2501-2507.

Duckett T, Brigell M, Ruckh S. Electroretinographic changes are not associated with loss of visual function in pediatric epileptic patients following treatment with vigabatrin. *Invest Ophthalmol Vis Sci* 1998;39:S973. Abstract.

Egge K. The visual field in normal subjects. *Acta Ophthalmol Scand* 1984;Suppl 169:1-64.

Ehinger B. Autoradiographic identification of rabbit retinal neurons that take up GABA. *Experientia* 1970;26:1063-1064.

Eke T, Talbot JF, Lawden MC. Severe persistent visual field constriction associated with vigabatrin. *BMJ* 1997;314:180-181.

Elder MJ. Diazepam and its effects on visual fields. *Aust N Z J Ophthalmol* 1992;20:267-270.

Engel J, Pedley TA. Introduction: What is epilepsy? In :Engel J, Pedley TA Ed:s Epilepsy. A comprehensive textbook. Philadelphia, Lippincott-Raven Publishers 1997:1-7.

Enz R, Brandstätter JH, Wässle H, Bormann J. Immunocytochemical localization of the GABA_C receptor **D** subunits in the mammalian retina. *J Neurosci* 1996;16:4479-4490.

Euler T, Wässle H. Different contributions of GABA_A and GABA_C receptors to rod and cone bipolar cells in a rat retinal slice preparation. *J Neurophysiol* 1998;79:1384-1395.

Faedda MT, Giallonardo AT, Marcetti A, Manfredi M. Terapia con vigabatrin nelle epilessie parziali resistenti. *G Neuropsicofarmacol* 1993;15:105-108.

Fakhoury T, Uthman B, Abou-Khalil B. Safety of long-term treatment with tiagabine. *Seizure* 2000a;9:431-435.

Fakhoury TA, Abou-Khalil B, Lavin P, Sommerville KW. Lack of visual field defects with long-term use of tiagabine. *Neurology* 2000b;54:A309.Abstract.

Falk G. Retinal physiology. In: Heckenlively JR and Arden GB, eds. Principles and practice of clinical electrophysiology of vision. St Louis, Mosby Year Book 1991:69-84.

Farnsworth D. The Farnsworth-Munsell 100-Hue Test. Baltimore: Munsell Color Company 1957

Feigenspan A, Bormann J. GABA-gated Cl⁻ channels in the rat retina. *Progr Ret Eye Res* 1998;17:99-126.

Ferris FL, Kassoff A, Bresnick GH, Bailey I. New visual acuity charts for clinical research. *Am J Ophthalmol* 1982;94:91-96.

Fink-Jensen A, Suzdak PD, Swedberg ME, Judge L, Hansen L, Nielsen PG. The (G)-aminobutyric acid (GABA) uptake inhibitor, tiagabine, increases extracellular brain levels of GABA in awake rats. *Eur J Pharmacol* 1992;220:197-201.

Galán F. Normal fields of vision with Goldmann perimetry. *Bibliotheca Ophthalmologica* 1968;6:52-61.

Gibson JP, Yarrington JT, Loudy DE, Gerbig CG, Hurst GH, Newberne JW. Chronic toxicity studies with vigabatrin, a GABA-transaminase inhibitor. *Toxicol Pathol* 1990; 18:225-238.

Giordano L, Valseriati D, Vignoli A, Morescalchi F, Gandolfo E. Another case of reversibility of visual-field defects induced by vigabatrin monotherapy: is young age a favorable factor? *Neurol Sci* 2000;21:185-186.

Glaser J, Savino P, Summers K, McDonald S, Knighton R. The photostress recovery test in the clinical assessment of visual function. *Am J Ophth.*1977;83:255-260.

Gross-Tsur V, Banin E, Shahar E, Shalev RS, Lahat E. Visual impairment in children with epilepsy

treated with vigabatrin. *Ann Neurol* 2000;48:60-64.

Gross-Selbeck G. Gesichtsfeldausfälle durch Vigabatrin. *Monatsschr Kinderheilk* 2000;148:373-374.

Guberman A, Bruni J, The Canadian Vigabatrin Study Group. Long-term open multicentre, add-on trial of vigabatrin in adult resistant partial epilepsy. *Seizure* 2000;9:112-118.

Harding GFA. Severe persistent visual constriction associated with vigabatrin. Four possible explanations exist. *BMJ* 1997; 314: 1694. Letter.

Harding GFA, Jones LA, Tipper VJ, Betts TA, Mumford JP. Electroretinogram, pattern electroretinogram, and visual evoked potential assessment in patients receiving vigabatrin. *Epilepsia* 1995;36:S108. Abstract.

Harding GFA, Robertson KA, Edson AS, Barnes P, Wild J. Visual electrophysiological effect of a GABA transaminase blocker. *Doc Ophthalmol* 1999;97:179-188.

Harding GFA, Wild JM, Robertson KA, Rietbrock S, Martinez C. Separating the retinal electrophysiologic effects of vigabatrin. Treatment versus field loss. *Neurology* 2000a;55:347-352.

Harding GFA, Wild JM, Robertson KA, Lawden MC, Bets TA, Barber C, Barnes PMF. Electro-oculography, electroretinography, visual evoked potentials, and multifocal electroretinography in patients with vigabatrin-attributed visual field constriction. *Epilepsia* 2000b;41:1420-1431.

Hardus P, Verduin WM, Postma G, Stilma JS, Berendschot TT, van Veelen CWM. Concentric contraction of the visual field in patients with temporal lobe epilepsy and its association with the use of vigabatrin medication. *Epilepsia* 2000a;41:581-587.

Hardus P, Verduin WM, Postma G, Stilma JS, Berendschot TTJM, van Veelen CWM. Long term changes in the visual fields of patients with temporal lobe epilepsy using vigabatrin. *Br J Ophthalmol* 2000b;84:788-790.

Hardus P, Verduin WM, Engelsman M, Edelbroek PM, Segers JP, Berendschot TT, Stilma JS. Visual field loss associated with vigabatrin: quantification and relation to dosage. *Epilepsia* 2001a;42:262-267.

Hardus P, Verduin WM, Berendschot TTJM, Kamermans M, Postma G, Stilma JS, van Veelen CWM. The value of electrophysiology results in patients with epilepsy and vigabatrin associated visual field loss. *Acta Ophthalmol Scand* 2001b;79:169-174.

Hardy LH, Rand G, Rittler MC. AO H-R-R Pseudoisochromatic plates. New York; American Optical Corporation 1957.

Harris JP, Phillipson OT. Effects of lorazepam on human contrast sensitivity. *Psychopharmacology* 1995;117:379-384.

Hart WM. Acquired dyschromatopsias. *Surv Ophthalmol* 1987;32:10-31.

Herbert M, Starreveld E, Kherani F, MacDonald I. Reduction in scotopic oscillatory potentials is

strongly correlated with the duration of vigabatrin therapy. *Invest Ophthalmol Vis Sci* 2000;41:S591. Abstract.

Hilton EJ, Cubbridge RP, Hosking S. Epilepsy patients treated with vigabatrin exhibit central visual function deficits. *Invest Ophthalmol Vis Sci* 2001;42:S845. Abstract.

Hirsch E. Correspondence to "Outer retinal dysfunction in patients treated with vigabatrin". *Neurology* 2000;54:1396. Letter.

Horiguchi M, Suzuki S, Kondo M, Tanikawa A, Miyake Y. Effect of glutamate analogues and inhibitory neurotransmitters on the electroretinograms elicited by random sequence stimuli in rabbits. *Invest Ophthalmol Vis Sci* 1998;39:2171-2176.

Hosking, SL, Roff Hilton EJ; Embleton SJ. Epilepsy patients treated with vigabatrin exhibit reduced ocular blood flow. *Invest Ophthalmol Vis Sci* 2001;42:S83. Abstract.

Hu M, Bruun A, Ehinger B. The expression of GABA_A receptors during the development of the rabbit retina. *Acta Ophthalmol Scand* 1998;76:515-520.

Hu M, Bruun A, Ehinger B. Expression of GABA transporter subtypes (GAT1, GAT3) in the adult rabbit retina. *Acta Ophthalmol Scand* 1999;77:255-260.

Humphrey Field Analyser II. User's Guide. Dublin CA, Humphrey Systems 1998.

Iannetti P, Spalice A, Perla FM, Conicella E, Raucci U, Bizzarri B. Visual field constriction in children with epilepsy on vigabatrin treatment. *Pediatrics* 2000;106:838-842.

Ichikawa H, Hukami K, Tanabe S. Standard Pseudoisochromatic Plates part 2. Tokyo: Igaku-Shoin Ltd. 1983.

Ichikawa K, Ichikawa H, Tanabe S. Detection of acquired color vision defects by Standard Pseudoisochromatic Plates part 2. In: Verriest G, ed. *Colour vision deficiencies VIII*. Dordrecht: Martinus Nijhoff/Dr W Junk Publishers, 1987; *Doc Ophthalmol Proc Ser* 46:133-40.

Ishihara S. The series of plates designed as a test for color-blindness. Tokyo: Kanehara&Co.Ltd. 1957.

Johnson MA, Krauss GL, Miller NR, Medura M, Paul SR. Visual function loss from vigabatrin: Effect of stopping the drug. *Neurology* 2000;55:40-45.

Kaufman KR, Lepore FE, Keyser BJ. Visual fields and tiagabine: a quandary. *Epilepsia* 2000;41:S227. Abstract.

Keltner JL, Johnson CA. Automated and manual perimetry- a six-year overview. Special emphasis on neuro-ophthalmic problems. *Ophthalmology* 1983;91:68-85.

Keränen T, Kälviäinen R, Sillanpää M. Epilepsiapotilaan lääkehoito. *Kapseli* 1997;27:9-70.

Kinnear PR. Proposals for scoring and assessing the 100-hue test. *Vision Res* 1970;10:423-433.

Kolb H. The neural organisation of the human retina. In: Heckenlively JR and Arden GB, eds. Principles and practice of clinical electrophysiology of vision. St Louis, Mosby Year Book 1991a:25-52.

Kolb H. Anatomical pathways for color vision in the human retina. *Visual Neuroscience* 1991b;7:61-74.

Krakow K, Polizzi G, Riordan-Eva P, Holder G, MacLeod WN, Fish DR. Recovery of visual field constriction following discontinuation of vigabatrin. *Seizure* 2000;9:287-290.

Krauss GL, Johnson MA, Miller NR. Vigabatrin-associated retinal cone system dysfunction. Electroretinogram and ophthalmologic findings. *Neurology* 1998;50:614-618.

Krämer G, Scollo-Lavizzari G, Jallon P, Blankenhorn V, Goumaz M, Bacher M, Bredel-Geisser A, Kaiser H. Vigabatrin-associated bilateral concentric visual field defects in four patients. *Epilepsia* 1997;38:S179. Abstract.

Krämer G, Ried S, Landau K, Harding GFA. Vigabatrin: Reversibility of severe concentric visual field defects after early detection and drug withdrawal: A case report. *Epilepsia* 2000;41 (Suppl Florence):144. Abstract.

Kupenova P, Vitanova L, Mitova L, Belcheva S. Participation of the GABAergic system of the turtle retina in the light adaptation process. *Acta Physiol Scand* 1991;141:203-210.

Kälviäinen R. Newly diagnosed epileptic seizure disorder in adults. A prospective follow-up study on 100 patients. Academic Dissertation. Kuopio University 1992.

Kälviäinen R, Keränen T, Riekkinen PJ Sr. Place of newer antiepileptic drugs in the treatment of epilepsy. *CNS Drugs* 1993;46:1009-1024.

Kälviäinen R, Äikiä M, Saukkonen A, Mervaala E, Riekkinen P Sr. Vigabatrin vs carbamazepine monotherapy in patients with newly diagnosed epilepsy. *Arch Neurol* 1995;52:989-996.

Kälviäinen R, Brodie M, Duncan J, Chadwick D, Edwards D, Lyby K. A double-blind, placebo-controlled trial of tiagabine given three-times daily as add-on therapy for refractory partial seizures. *Epilepsy Res* 1998;30:31-40.

Kälviäinen R, Salmenperä T, Jutila L, Äikiä M, Nousiainen I, Riekkinen P, Sr. Tiagabine monotherapy in chronic partial epilepsy. *Epilepsia* 1999;40:S258. Abstract.

Kälviäinen R, Hache JC, Renault- Djouadi J. A study of visual fields in patients receiving tiagabine as monotherapy and matched controls receiving carbamazepine or lamotrigine monotherapy. *Epilepsia* 2000;41 (Suppl Florence):145. Abstract.

Laplace O, Rigolet H, Nordmann JP. Electro-oculogram in epileptic patients treated by vigabatrin: efficacy or toxicity test? *Invest Ophthalmol Vis Sci* 2000;41:S78. Abstract.

Lawden MC, Eke T, Degg C, Harding GFA, Wild JM. Visual field defects associated with vigabatrin therapy. *J Neurol Neurosurg Psychiatry* 1999;67:716-722.

Leach JP, Rao P, Ahlfat F, Kyle G, Chadwick DW. Vigabatrin and visual field defects: is there a link? *Epilepsia* 1998;39:S58. Abstract.

Leach JP, Brodie MJ. Tiagabine. *Lancet* 1998;351:203-207.

Leppik IE, Gram L, Deaton R, Sommerville KW. Safety of tiagabine: summary of 53 trials. *Epilepsy Research* 1999;33:235-246.

Li SG, Spaeth GL, Scimeca HA, Schatz NJ, Savino PJ. Clinical experiences with the use of an automated perimeter (Octopus) in the diagnosis and management of patients with glaucoma and neurologic diseases. *Ophthalmology* 1979;86:1302-1316.

Lindberger M, Alenius M, Frisén L, Johannessen SI, Larsson S, Malmgren K, Tomson T. Gabapentin versus vigabatrin as first add-on for patients with partial seizures that failed to respond to monotherapy: a randomized, double-blind, dose-titration study. *Epilepsia* 2000;41:1289-1295.

Llerda MJ, Lasaosa SS, Juste TC, Cortina EI, Martinez IC, Asin MF. Visual field defects associated with vigabatrin therapy: Prevalence, characteristics and follow-up. *Epilepsia* 2000;41:S240. Abstract.

Loiseau P. Review of controlled trials of Gabitril (Tiagabine): A clinician's viewpoint. *Epilepsia* 1999;40:S14-S19.

López L, Thomson A, Rabinowicz L. Assessment of colour vision in epileptic patients exposed to single-drug therapy. *Eur Neurol* 1999;41:201-205.

Lorenz R, Kuck H. Visuelle Störungen durch Diphenylhydantoin: Klinische und elektro-ophthalmologische Befunde. *Kl Mbl Augenheilk* 1988;192:244-247.

Lowes M. Peripheral visual field restriction in chloroquine retinopathy. *Acta Ophthalmol* 1976;54:819-826.

Luchetti A, Amadi A, Gobbi G, Bertani G. Visual field defects associated with vigabatrin therapy in children. *J Neurol Neurosurg Psychiatry*. 2000;69:556. Letter.

Lux AL, Edwards SW, Osborne JP, Hancock E, Johnson AL, Kennedy CR, O'Callaghan FJK, Newton RW, Verity CM. Revised guideline for prescribing vigabatrin in children. Guideline's claim about infantile spasms is not based on appropriate evidence. *BMJ* 2001;322:236. Letter.

Maaranen TH, Tuppurainen KT, Mäntyjärvi MI. Color vision defects after central serous chorioretinopathy. *Retina* 2000;20:633-637.

Macdonald R, Kelly K. Mechanisms of action of currently prescribed and newly developed antiepileptic drugs. *Epilepsia* 1994; 35:41-50.

Mackenzie R, Klistorner A. Severe persistent visual constriction associated with vigabatrin. Asymptomatic as well as symptomatic defects occur with vigabatrin. *BMJ* 1998;316:232. Letter.

Malmgren K, Ben-Menachem E, Frisen L. Vigabatrin visual toxicity: Evolution and dose dependence. *Epilepsia* 2001;42:609-615.

Manji H, Plant GT. Epilepsy surgery, visual fields, and driving: a study of the visual field criteria for driving in patients after temporal lobe epilepsy surgery with a comparison of Goldmann and Esterman perimetry. *J Neurol Neurosurg Psychiatry* 2000;68:80-82.

Manuchehri K, Goodman S, Siviter L, Nightingale S. A controlled study of vigabatrin and visual abnormalities. *Br J Ophthalmol* 2000;84:499-505.

Marmor MF, Arden GB, Nilsson SEG, Zrenner E. Standard for clinical electroretinography. *Arch Ophthalmol* 1989;107:816-819.

Marson AG, Kadir ZA, Hutton JL, Chadwick DW. The new antiepileptic drugs: a systematic review of their efficacy and tolerability. *Epilepsia* 1997;38:859-880.

Marson AG, Chadwick DW. New drug treatments for epilepsy. *J Neurol Neurosurg Psychiatry* 2001;70: 143-147.

Massey SC, Redburn DA. A tonic γ -aminobutyric acid-mediated inhibition of cholinergic amacrine cells in rabbit retina. *J Neurosci* 1982;11:1633-1643.

Mattson RH, Cramer JA, Collins JF, Smith DB, Delgado-Escueta AV, Browne TR, Williamson PD, Treiman DM, McNamara JO, McCutchen CB, Homan RW, Crill WE, Lubozynski MF, Rosenthal NP, Mayersdorf A. Comparison of carbamazepine, phenobarbital, phenytoin, and primidone in partial and secondarily generalized tonic-clonic seizures. *N Engl J Med* 1985; 313: 145-151.

Mattson RH, Cramer JA, Collins JF. A comparison of valproate with carbamazepine for the treatment of complex partial seizures and secondarily generalized tonic clonic seizures in adults. The Department of Veterans Affairs Epilepsy Cooperative Study No. 264 Group. *N Engl J Med* 1992; 327: 765-771.

Mattson RH. Carbamazepine. In:Engel J Jr, Pedley TA,eds. *Epilepsy. A comprehensive textbook* Vol 2. Philadelphia: Lippincott-Raven 1998;1491-1502.

Mauguière F, Chauvel P, Dewailly J, Dousse N and the PMS Study Multicenter Group. No effect of long-term vigabatrin treatment on central nervous system conduction in patients with refractory epilepsy: results of a multicenter study of somatosensory and visual evoked potentials. *Epilepsia* 1997;39:301-308.

McDonagh J, Grierson DJ, Keating D, Parks S. The wide field multifocal ERG reveals a retinal defect caused by vigabatrin toxicity? *Br J Ophthalmol* 2001;85:119-120. Letter.

Mecarelli O, Rinalduzzi S, Accornero N. Changes in color vision after a single dose of vigabatrin or carbamazepine in healthy volunteers. *Clin Neuropharmacol* 2001;24:23-26.

Meldrum BS. Anatomy, physiology, and pathology of epilepsy. *The Lancet* 1990;336:231-234.

Mervaala E, Partanen J, Nousiainen U, Sivenius J, Riekkinen P. Electrophysiologic effects of gamma-vinyl GABA and carbamazepine. *Epilepsia* 1989;30:189-193.

Midelfart A, Midelfart E, Brodtkorb E. Visual field defects in patients taking vigabatrin. *Acta*

Ophthalmol Scand 2000;78:580-584.

Miller NR, Johnson MA, Paul SR, Girkin CA, Perry JD, Endres M, Krauss GL. Visual dysfunction in patients receiving vigabatrin. Clinical and electrophysiologic findings. *Neurology* 1999;53:2082-2087.

Miller NR. Using the electroretinogram to detect and monitor the retinal toxicity of anticonvulsants. Editorial. *Neurology* 2000;55:333-334.

Morales J, Brown SM. The feasibility of short automated static perimetry in children. *Ophthalmology* 2001;108:157-162.

Morimoto K, Sato H, Yamamoto Y, Watanabe T, Suwaki H. Antiepileptic effects of tiagabine, a selective GABA uptake inhibitor, in the rat kindling model of temporal lobe epilepsy. *Epilepsia* 1997;38:966-974.

Myers VS, Gidlewski N, Quinn GE, Miller D, Dobson V. Distance and near visual acuity, contrast sensitivity, and visual fields of 10-year-old children. *Arch Ophthalmol* 1999;117:94-99.

Mäntyjärvi M, Laitinen TL. Normal values of the Pelli-Robson contrast sensitivity test. *J Cataract Refract Surg* 2001;27:261-266.

Mäntyjärvi M. Normal test scores of the Farnsworth-Munsell 100 Hue Test. *Doc Ophthalmol* 2001;102:73-80.

Napper GA, Kalloniatis M. Glutamate and GABA uptake and metabolism in retinal glial cells. *Invest Ophthalmol Vis Sci* 1995;36:S286. Abstract.

Neal MJ, Cunningham JR, Shah MA, Yazulla S. Immunocytochemical evidence that vigabatrin in rats causes GABA accumulation in glial cells of the retina. *Neuroscience Lett* 1989;98:29-32.

Neal MJ, Shah MA. Development of tolerance to the effects of vigabatrin (γ -vinyl-GABA) on GABA release from rat cerebral cortex, spinal cord and retina. *Br.J.Pharmacol.* 1990;100:324-328.

Newman WD, Tocher K, Acheson JF. Vigabatrin associated visual field loss: Prevalence and natural history. Proceedings of the 13th Meeting of the International Neuro-Ophthalmology Society INOS-2000, september 10-13, 2000. Toronto, Ontario, Canada. *Neuro-Ophthalmology* 2000;23:205. Abstract.

Olsson J, Åsman P, Heijl A. A perimetric learner's index. *Acta Ophthalmol Scand* 1997;75:665-668.

Osborne JP, Edwards SW, Hancock E, Lux AL, O'Callaghan F, Johnson T, Kennedy CR, Newton RW, Verity CM. Infantile spasms and vigabatrin. Study will compare effects of drugs. *BMJ* 1999;318:56-57.

Paul SR, Krauss GL, Miller NR, Medura MT, Miller TA, Johnson MA. Visual function is stable in patients who continue long-term vigabatrin therapy: Implications for clinical decision making. *Epilepsia* 2001;42:525-530.

Paulus W, Schwarz G, Steinhoff BJ. The effect of anti-epileptic drugs on visual perception in patients with epilepsy. *Brain* 1996;119:539-549.

Paulus W, Schwarz G, Steinhoff BJ. The effect of carbamazepine, phenytoin and valproic acid anti-epileptic convulsive drugs on visual perception. In: Cavonius CR ed. *Colour Vision Deficiencies XIII. Proceedings of the Thirteenth Symposium of the International Research Group on Colour Vision Deficiencies*; 1995 July 27-30; Pau, France. Dordrecht: Kluwer Academic publishers, 1997:187-191.

Pelli D, Robson J, Wilkins A. The design of a new letter chart for measuring contrast sensitivity. *Clin Vision Sci* 1988;2:187-199.

Perez M-TR, Davanger S. Distribution of GABA immunoreactivity in kainic acid-treated rabbit retina. *Exp Brain Res* 1994;100:227-238.

Perlman I, Normann RA. The effects of GABA and related drugs on the horizontal cells in the isolated turtle retina. *Visual Neuroscience* 1990;5:469-477.

Perron AM, Westall CA, Mirabella G, Buncic JR, Logan WJ, Snead OC. Contrast sensitivity changes in children prescribed the anti-epileptic drug vigabatrin. *Invest Ophthalmol Vis Sci* 2001;42:S388. Abstract.

Petroff OAC, Hyder F, Collins T et al. Acute effects of vigabatrin on brain GABA and homocarnosine in patients with complex partial seizures. *Epilepsia* 1999;40:958-964.

Plazonnet BA, Bonhomme B, Chazel J, Viallefont J, Doly M. In-vitro vigabatrin alters the electroretinogram of the isolated rat retina. *Invest Ophthalmol Vis Sci* 2001;42:S179. Abstract.

Ponjavic V, Andreasson S. Multifocal ERG and full-field ERG in patients on long-term vigabatrin medication. *Doc Ophthalmol* 2001;102:63-72.

Pow DV, Baldrige W, Crook DK. Activity-dependent transport of GABA analogues into specific cell types demonstrated at high resolution using a novel immunocytochemical strategy. *Neuroscience* 1996;73:1129-1143.

Prager TC. Essential factors in testing for glare. In: Nadler MP, Miller D, Nadler D ed:s. *Glare and contrast sensitivity for clinicians*. New York, Springer-Verlag 1990:33-44.

Prasad AN, Penney S, Buckley DJ. The role of vigabatrin in childhood seizure disorders: results from a clinical audit. *Epilepsia* 2001;42:54-61.

Rao PG, Al Fat F, Kyle G, Leach JP, Chadwick DW, Batterbury M. Study is needed of visual field defects associated with any long term antiepileptic drug. *BMJ* 1998;317:206. Letter.

Ravindran J, Blumbergs P, Crompton J, Pietris G, Waddy H. Visual field loss associated with vigabatrin: pathological correlations. *J Neurol Neurosurg Psychiatry* 2001;70:787-789.

Rebolleda G, Munoz-Negrete FJ, Gutierrez C. Screening of patients taking vigabatrin. *Ophthalmology* 2000;107:1219-1220. Letter.

Riikonen RS. Steroids or vigabatrin in the treatment of infantile spasms? *Pediatr Neurol* 2000;23:403-408.

Rintahaka P, Granström M, Lappi M, Gaily E, Liukkonen E, Paetau R. Visual field defects in vigabatrin-treated children with epilepsy. *Epilepsia* 2000;41:S196-S197. Abstract.

Roth A. Metameric matches relevant for assessment of color vision II. Practical aspects. In: Verriest G, ed. *Colour Vision Deficiencies VII. Doc Ophthalmol Proc Ser 39*. The Hague: Dr W Junk Publishers 1984:95-109.

Rubin G. Reliability and sensitivity of clinical contrast sensitivity tests. *Clin Vision Sci* 1988;2:169-177.

Ruether K, Pung T, Kellner U, Schmitz B, Hartmann C, Seeliger M. Electrophysiologic evaluation of a patient with peripheral visual field contraction associated with vigabatrin. *Arch Ophthalmol* 1998;116:817-819.

Ruiz M, Egel H, Sarthy V, Qian X, Sarkar HK. Cloning, expression and localization of a mouse retinal γ -aminobutyric acid transporter. *Invest Ophthalmol Vis Sci* 1994;35:4039-4048.

Russell-Eggitt IM, Mackey DA, Taylor DSI, Timms C, Walker JW. Vigabatrin-associated visual field defects in children. *Eye* 2000;14:334-339.

Saletu B, Grünberger J, Linzmayer L, Schwartz J, Haegele K, Schechter P. Psychophysiological and psychometric studies after manipulating the GABA system by vigabatrin, a GABA-transaminase inhibitor. *Int J Psychophysiol* 1986;4:63-80.

Sartucci F, Massetani R, Galli R, Bonanni E, Tognoni G, Milani S, Iudice A, Murri L. Visual contrast sensitivity in carbamazepine-resistant epileptic patients receiving vigabatrin as add-on therapy. *JEpilepsy* 1997;10:7-11.

Schechter PJ, Tranier Y, Jung MJ, Böhlen P. Audiogenic seizure protection by elevated brain GABA concentration in mice: effects of gamma-acetylenic GABA and gamma-vinyl GABA, two irreversible GABA-T inhibitors. *Eur J Pharmacol* 1977;45:319-328.

Schiefer U, Eter N, Lun S, Besch D, Burth R, Spitznas M, Elger CE. What is typical about vigabatrin-associated visual field defects? Proceedings of the 13th Meeting of the International Neuro-Ophthalmology Society INOS-2000, september 10-13, 2000. Toronto, Ontario, Canada. *Neuro-Ophthalmology* 2000;23:206. Abstract.

Schindler S, McCrary JA. Automated perimetry in a neuro-ophthalmological practice. *Annals of Ophthalmol* 1981;13:691-697.

Schmidt T, Schmitz B, Jokiel B, Tiel-Wilck K, Ruether K. Constriction of the visual field in epilepsy patients taking vigabatrin and other antiepileptic drugs: A longitudinal study. *Epilepsia* 1999;40:S256. Abstract.

Schmidt T, Jokiel B, Tiel-Wilck K, Ruether K, Schmitz B. Are vigabatrin-associated visual field constrictions reversible? *Epilepsia* 2000;41(Suppl Florence):S144. Abstract.

Schmitz B, Jokiel B, Schmidt T, Tiel-Wilck K, Ruether K. Visual field defects under treatment with vigabatrin, carbamazepine and valproate: a prospective study. *Epilepsia* 1999;40:S257. Abstract.

Schroeder CE, Gibson JP, Yarrington J, Heydorn WE, Sussman NM, Arezzo JC. Effects of high dose gamma-vinyl-GABA (vigabatrin) administration on visual and somatosensory evoked potentials in dogs. *Epilepsia* 1992;33:S13-S25.

Sills GJ, Patsalos PN, Butler E, Forrest G, Ratnaraj N, Brodie MJ. Visual field constriction: Accumulation of vigabatrin but not tiagabine in the retina. *Neurology* 2001;57:196-200.

Sivenius J, Paljärvi L, Vapalahti M, Nousiainen U, Riekkinen PJ. Vigabatrin (γ-vinyl-GABA): Neuropathologic evaluation of five patients. *Epilepsia* 1993;34:193-196.

Slaughter MM, Tian N. You cannot inhibit a good receptor: GABA receptor diversity in the vertebrate retina. In: Shapley R, Lam DMK, ed:s. *Contrast Sensitivity. (Proceedings of the Retina Research Foundation Symposia, Vol 5)*. Massachusetts Institute of Technology, 1993:59- 74.

Smith V, Pokorny J, Pass A. Color-axis determination on the Farnsworth-Munsell 100-hue test. *Am J Ophthalmol* 1985;100:176-182.

Sosiaali- ja terveystieteiden ministeriön päätös n:o 1012 (STM 1012/86) tapaturmavakuutuslain 18 a §:ssä tarkoitettusta haittaluokituksesta. Helsinki, Valtion painatuskeskus 1986.

Spanaki MV, Siegel H, Kopylev L, Fazilat S, Dean A, Liow K, Ben-Menachem E, Gaillard WD, Theodore WH. The effect of vigabatrin (γ-vinyl GABA) on cerebral blood flow and metabolism. *Neurology* 1999;53:1518-1522.

Specchio L, Bellizzi M, La Neve A, Boero G, Specchio N, Auteri P, Cantatore F, Procoli U, Ciccolella N. Visual impairment in adult epileptic patients treated with vigabatrin. *Neurology* 2000;54:A308. Abstract.

Stefan H, Bernatik J, Knorr J. Gesichtsfeldstörungen bei Antiepileptikabehandlung. *Nervenarzt* 1999;70:552-555.

Steinhoff B, Freudenthaler N, Paulus W. The influence of established and new antiepileptic drugs on visual perception I. A placebo-controlled, double blind, single-dose study in healthy volunteers. *Epilepsy Res* 1997a;29:35-47.

Steinhoff B, Freudenthaler N, Paulus W. The influence of established and new antiepileptic drugs on visual perception II. A controlled study in patients with epilepsy under long-term antiepileptic medication. *Epilepsy Res* 1997b;29:49-58.

Suzdak PD, Jansen JA. A review of the preclinical pharmacology of tiagabine: A potent and selective anticonvulsant GABA uptake inhibitor. *Epilepsia* 1995;36:612-626.

Szlyk JP, Seiple W, Fishman GA, Alexander KR, Grover S, Mahler CL. Perceived and actual performance of daily tasks: relationship to visual function tests in individuals with retinitis pigmentosa. *Ophthalmology* 2001;108:65-75.

Tanabe S, Hukami K, Ichikawa H. New pseudoisochromatic plates for acquired color vision defects. In: Verriest G, ed. Colour Vision Deficiencies VII. Doc Ophthalmol Proc Ser 39. The Hague: Dr W Junk Publishers 1984:199-204.

Tiel-Wilck K, Jokiel B, Zinser P, Heine Fr, Pfeiffer S, Wilck B et al . Afferent visual function after single dose application of γ -vinyl GABA. Neuro-ophthalmology 1995;15:305-310.

Tomson T, Nilsson BY, Levi R. Impaired visual contrast sensitivity in epileptic patients treated with carbamazepine. Arch Neurol 1988;45:897-900.

Tomson T, Johannessen SI. Therapeutic monitoring of the new antiepileptic drugs. Eur J Clin Pharmacol 2000;55:697-705.

Trauzettel-Klosinski S. Untersuchungsstrategien bei Simulation und funktionellen Sehstörungen. KI Monatsbl Augenheilk 1997;211:73-83.

Trojan H. Gesichtsfeldbefunde bei symptomatischen Epilepsie. Mbl Augenheilk 1967;150:718-721.

Valdizan EM, Garcia AP, Armijo JA. Time course of the GABAergic effects of vigabatrin: Is the time course of brain GABA related to platelet GABA-transaminase inhibition? Epilepsia 1999;40:1062-1069.

Van Haesendonck E, Missotten L. A subgroup of bipolar cells in the human retina is GABA-immunoreactive. Neurosci Lett 1993;161:187-190.

Vanhatalo S, Pääkkönen L, Nousiainen I. Visual field constriction in children treated with vigabatrin. Neurology 1999;52:1713-1714.

Vanhatalo S, Alen R, Riikonen R, Rantala H, Aine M-R, Mustonen K, Nousiainen I. Reversed visual field constrictions in children after vigabatrin withdrawal - true retinal recovery or improved test performance only? Seizure 2001. In press.

Van Parys JAP, de Beer-Pawlikowski NKB, Edelbroek PM. Vigabatrin and serum aminotransferases. Epilepsia 1995;36:108. Abstract.

Vecchio A, Roccella M. Study of the visual field in pediatric patients with focal epilepsy in monotherapy with vigabatrin: Preliminary data. Epilepsia 2000;41:S144. Abstract.

Verriest G, Van Laethem J, Uvijls A. A new assessment of the normal ranges of the Farnsworth-Munsell 100-Hue test scores. Am J Ophthalmol 1982;93:635-642.

Versino M, Veggiotti P. Reversibility of vigabatrin-induced visual-field defect. Lancet 1999;354:486. Letter.

Vesti Nielsen N, Syversen K. Possible retinotoxic effect of carbamazepine. Acta Ophthalmol 1986;64:287-290.

Vigabatrin Advisory Group. Guideline for prescribing vigabatrin in children has been revised. BMJ 2000;320:1404. Letter.

Vigabatrin Advisory Group. Advisory group's reply. *BMJ* 2001;322:236. Letter.

Westall CA, Smith K, Logan WJ, Buncic JR, Panton CM, Khan A. Longitudinal investigation of ERGs in children on vigabatrin therapy. *Invest Ophthalmol Vis Sci* 2000;41:S35. Abstract.

Whiteside JA. Peripheral vision in children and adults. *Child Development* 1976;47:290-293.

Wild JM, Searle AET, Dengler-Harles M, O'Neill EC. Long-term follow-up of baseline learning and fatigue effects in the automated perimetry of glaucoma and ocular hypertensive patients. *Acta Ophthalmol Scand* 1991;69:210-216.

Wild JM, Martinez C, Reinshagen G, Harding GFA. Characteristics of a unique visual field defect attributed to vigabatrin. *Epilepsia* 1999;40:1784-1794.

Wilson EA, Brodie MJ. Severe persistent visual constriction associated with vigabatrin. Chronic refractory epilepsy may have a role in causing these unusual lesions. *BMJ* 1997;314:1693. Letter.

Wilton LV, Stephens MDB, Mann RD. Visual field defect associated with vigabatrin: observational cohort study. *BMJ* 1999;319:1165-1166.

Wohlrab G, Boltshauser E, Schmitt B, Schriever S, Landau K. Visual field constriction is not limited to children treated with vigabatrin. *Neuropediatrics* 1999;30:130-132.

Wolfe JM. An introduction to contrast sensitivity testing. In: Nadler MP, Miller D, Nadler D ed:s. *Glare and contrast sensitivity for clinicians*. New York, Springer-Verlag 1990:5-23.

Wong ICK, Mawer GE, Sander JWAS. Severe persistent visual constriction associated with vigabatrin. Reaction may be dose dependent. *BMJ* 1997;314:1693-1694. Letter.

Ylinen A, Kälviäinen R, Riekkinen Sr. PJ. Long-term efficacy and cognitive effects of vigabatrin. *Acta Neurol Scand* 1995;Suppl 162:47-50.

Ylinen A, Salmenperä T, Mumford JP, Riekkinen PJ. Long-term treatment with vigabatrin- 10 years of clinical experience. *Seizure* 1999;8:181-183.

Zaccara G, Gangemi PF, Messori A, Parigi A, Massi S, Valenza T, Monza GC. Effects of oxcarbazepine and carbamazepine on the central nervous system: computerised analysis of saccadic and smooth-pursuit eye movements. *Acta Neurol Scand* 1992;85:425-429.

Zgorzalewicz M, Calas-Zgorzalewicz B. Visual and auditory evoked potentials during long-term vigabatrin treatment in children and adolescents with epilepsy. *Clin Neurophysiology* 2000;111:2150-2154.

Zrenner E, Nowicki J. Medikamentös induzierte Funktionsstörungen der Zapfenfunktion und Zapfeninteraktion. *Fortschr Ophthalmol* 1985;82:589-594.

Zucker C, Paryani G. Immunohistochemical localization of L-baclofen binding in the rabbit retina. *Invest Ophthalmol Vis Sci* 1998;39:S980. Abstract.

9 ORIGINAL PUBLICATIONS I-V